JOURNAL OF THE PHILIPPINE MEDICAL ASSOCIATION

Volume 99, Number 1 June - December 2020

Antimicrobial and Barrier Repair Properties of Virgin Coconut Oil and Mineral Oil in Pediatric Atopic Dermatitis Patients, A Randomized, Double-Blind, Control Trial
Claudine Joy M. Ramos, MD

Computer-Aided Detection of Pulmonary Tuberculosis and Pulmonary Cavity on Adult Chest Radiographs using a Region Convolutional Neural Network
Kevin Eric R. Santos, MD

Parental Perception and Attitude on Childhood Immunization and Other Government Healthcare Programs after the Dengue Vaccine Controversy: A Hospital-Based-Cross-Sectional Study
Elaine Diane Santos-Sanchez, MD

Retropharyngeal Sinus Tract Secondary to Glass Shard Impaction in an 8 Month-Old Child; Endoscopic Diagnosis via Telescope Endoscopy And Management of Sinus Tract by Endoscopic Electrocauterization
Angelo Miguel P. Parungao, MD
Antonio H. Chua, MD, FPSO-HNS

Orthotic Management with a Customized Humeral Brace for Gorham-Stout Disease of the Humerus: A Case Report
Margaux Mae M. Rayos, MD

Complete Mid Superior Sagittal Sinus Transection
Cheryl Joy B. Biado, MD

Mayer-Rokitansky-Küster-Hauser Syndrome
Miracle Faith H. Emano, MD

Disseminated Zoster in an Immunocompromised
Claudine Joy M. Ramos, MD

CT Scan Guided Interscalene Brachial Plexus Neurolysis using 95% Alcohol in a Patient with Neurogenic Thoracic Outlet Syndrome: A Case Report
Deanne D. Roscom, MD

Two Wrongs Make a Right: A Case Report on the Anesthetic Management of a Pediatric Patient with Congenitally Corrected Transposition of Great Arteries
Karla Adrielle N. Villasin, MD; Mariza M. Yumang, MD, DPBA

Anesthetic Management of a Pediatric Patient Diagnosed with Bilateral Hereditary Pheochromocytoma: A Case Report
Miguel Angelo Poblete, MD

TABLE OF CONTENTS

Journal of the
PHILIPPINE MEDICAL ASSOCIATION
VOLUME 99, NUMBER 1 ▪ June - December 2020

Antimicrobial and Barrier Repair Properties of Virgin Coconut Oil and Mineral Oil in Pediatric Atopic Dermatitis Patients, A Randomized, Double-Blind, Control Trial **1**
Claudine Joy M. Ramos, MD

Computer-Aided Detection of Pulmonary Tuberculosis and Pulmonary Cavity on Adult Chest Radiographs using a Region Convolutional Neural Network **10**
Kevin Eric R. Santos, MD

Parental Perception and Attitude on Childhood Immunization and Other Government Healthcare Programs after the Dengue Vaccine Controversy: A Hospital-Based-Cross-Sectional Study **22**
Elaine Diane Santos-Sanchez, MD

Retropharyngeal Sinus Tract Secondary to Glass Shard Impaction in an 8 Month-Old Child; Endoscopic Diagnosis via Telescope Endoscopy And Management of Sinus Tract by Endoscopic Electrocauterization **36**
Angelo Miguel P. Parungao, MD
Antonio H. Chua, MD, FPSO-HNS

Orthotic Management with a Customized Humeral Brace for Gorham-Stout Disease of the Humerus A Case Report **42**
Margaux Mae M. Rayos, MD

Complete Mid Superior Sagittal Sinus Transection **47**
Cheryl Joy B. Biado, MD

Mayer-Rokitansky-Küster-Hauser Syndrome **51**
Miracle Faith H. Emano, MD

Disseminated Zoster in an Immunocompromised **57**
Claudine Joy M. Ramos, MD

CT Scan Guided Interscalene Brachial Plexus Neurolysis using 95% Alcohol in a Patient with Neurogenic Thoracic Outlet Syndrome: A Case Report **63**
Deann D. Roscom, MD

Two Wrongs Make a Right: A Case Report on the Anesthetic Management of a Pediatric Patient with Congenitally Corrected Transposition of Great Arteries **67**
Karla Adrielle N. Villasin, MD; Mariza M. Yumang, MD, DPBA

Anesthetic Management of a Pediatric Patient Diagnosed with Bilateral Hereditary Pheochromocytoma: A Case Report **72**
Miguel Angelo Poblete, MD

Journal of the
PHILIPPINE MEDICAL ASSOCIATION
VOLUME 99, NUMBER 1 ▪ June - December 2020

Editorial Office:
2nd Floor PMA Building, North Avenue, Quezon City 1105 Philippines
Contact Numbers: +(632) 929-7361; +(632)929-6366; Fax: +(632) 929-6951
Website: www.philippinemedicalassociation.org;
E-mails: info@philippinemedicalassociation
philmedas@yahoo.com; philmedas@gmail.com

MARIA CHRISTINA H. VENTURA, MD
Editor in Chief

ARNEL M. ASIÑO, MD
RAQUEL B. CORREA, MD
Editors

PMA NATIONAL OFFICERS AND BOARD OF GOVERNORS

BENITO P. ATIENZA, MD
President

CHRISTINE S. TINIO, MD
Vice President

DURES FE E. TAGAYUNA, MD
National Treasurer

HECTOR M. SANTOS JR., MD
Secretary General

MARIA CHRISTINA H. VENTURA, MD
Asst. Secretary General

ROSA LINA M. BALOT, MD
Northeastern Luzon

JOSE MANUEL VICENTE C. BELLO JR., MD
Northwestern Luzon

AUGUSTO F. ABELEDA JR., MD
Central Luzon

ALEJANDRO Y. TAN, MD
Manila

MA. MERCEDES V. AGUSTIN, MD
Quezon City

ELISA O. TIU, MD
Rizal

JOSE ARNEL G. MANALILI, MD
Central Tagalog

ROSALINA S. CARAAN, MD
Southern Tagalog

RICARDO D. ISIP JR., MD
Bicol

JAPHET G. FERNANDEZ DE LEON, MD
Western Visayas

KAZAN BENIGNO S. BALUYOT, MD
Central Visayas

GLENDA G. OSERRAOS, MD
Eastern Visayas

JOHN HERNANI V. ANACAN JR., MD
Western Mindanao

LESTER LLOYD C. LEOCADIO, MD
Northern Mindanao

LUZ P. ACOSTA-BARRIENTOS, MD
Southeastern Mindanao

JACQUELINE L. ASENTISTA, MD
Northcentral Mindanao

MANOLITO C. GO, MD
Caraga

Journal of the
PHILIPPINE MEDICAL ASSOCIATION
VOLUME 99, NUMBER 1 ▪ June - December 2020

MESSAGE

Warmest greetings to everyone!

The research papers featured in this PMA Journal are the winners of the Resident's Research Competition for 2020-2021 and other written works that were selected for publication by the Committee on Publications of the Philippine Medical Association.

The Philippine Medical Association advocates the Continuing Professional Development Law to improve the practice of medical profession by our Filipino doctors. These and other research papers are original resources submitted by the residents from the different healthcare institutions, specialty organizations, medical schools, and universities and have been thoroughly reviewed and selected for publication by the Committee on Publications of the PMA.

We hope that this journal will provide you further knowledge and skills enhancement as you continue to fulfil your oath as physicians and promote quality healthcare for all Filipinos.

On behalf of the National Officers and the Board of Governors, our sincerest thanks and congratulations to the resident physicians for their participation, hard work, and diligence in accomplishing these research papers despite the challenges that we all faced and are still encountering amid this pandemic!

Mabuhay tayong lahat! PMA: Working together as one!

BENITO P. ATIENZA, MD
President, Philippine Medical Association

Journal of the

PHILIPPINE MEDICAL ASSOCIATION

Instruction for Authors

General Information

The Journal of the Philippine Medical Association (JPMA) is the official publication of the Philippine Medical Association (PMA).

The JPMA is published twice in a year at the PMA Office, 2nd Floor, PMA Building, North Avenue, Quezon City 1105, Philippines. It publishes original scientific papers pertinent to medicine and allied fields. It also considers for republications of previously published articles, either in their original or modified forms, provided they are accompanied by written permission from the publisher and principal author.

Statements and opinions expressed the articles and communications herein are those of the author(s) and not necessarily those of the Editor(s) or the publisher. The editor(s) and publisher disclaim any responsibility or liability for such materials and do not guarantee, warrant or endorse any product or services advertised in this publication.

No part of the articles and communications published in the JPMA may be reproduced without the written permission of the publisher.

Editorial Policies

The JPMA is a peer-review journal designed to meet the continuing education requirements of PMA members and the medical community. It adheres to the guidelines established by the International Community of Medical Journal Editors (ICMJE); however, for purposes of this issue, the previously circulated JPMA Instructions for Authors, although with some modifications, are still being followed.

Ethical Cosiderations

In the conduct and reporting of research, the JPMA adheres to the ethical considerations set forth by the ICMJE with respect to authorship and and contributorship, editorship, peer review, conflicts of interest, right to privacy and confidentiality of patients, study participants as well as authors and reviewers; and, the protection of human subjects and animals in research.

All financial or personal relationships that could be viewed as presenting a potential conflict of interest must be disclosed by the author(s) and all participants in the review and publication process.

In experiments involving human subjects, authors must indicate in their reports whatever procedures are complaint with the standards of the responsible institutional and national committee on human experimentation as well as with the Helsinki Declaration of 1975, as revised in 2000. In case of doubts as to the procedures, authors mush show proof of approval of their institutional review body or its equivalent.

In experiments involving animals, authors must indicate in their reports compliance with the institutional and national guide for laboratory animal experimentation.

Manuscript Preparation

(This section is primarily based on the previous and existing JPMA Instructions to Contributors but with some modifications based on the ICMJE recommendations. A completely revised version based on the guidelines of the ICMJE will be published in the next issue.

Accompanied by a cover letter from the principal author, the manuscripts, figures, tables, photographs, and references should be submitted in duplicate (an original and a copy) and typed double-space (including legends and footnotes) on one side of a white bond paper, 8.5 and 11 inches properly numbered consecutively on the upper right-hand corner of each page beginning with the title page. Illustrations must also be in duplicates. An electronic copy of the articles in a CD must be submitted.

The first page should contain the title, subtitle (if any, all authorsí full names and highest earned academic degrees, and hospital or institutional affiliations. It must also include disclaimer, if any.

For the original article, an abstract must be type at the beginning of each paper after the title. It must contain, in structured format, the following: background or context of the study, objectives, methods, results and conclusions of the study, as appropriate. It must not be more than 300 words. No footnotes/references must be in the abstract. For other articles, an unstructured abstract may be preferred. Below the abstractr, identify three to ten keywords or short phrases that will assist in indexers in cross-indexing the article.

Abbreviations and nomenclatures: the use of abbreviations should be minimized and preferably confined to tables only; non-standard abbreviations must be accompanied by legends.

Generic names of drugs are preferred. Trade names may be given only once at the end of the paper or in the acknowledgement and should follow the generic name in parenthesis.

References are to be cited consecutively in the text as superscripts numbers. At the end of each article, references should be listed consecutively in the numerical order as they appeared in the text

Advertisement

Interested advertisers shall be sent advertising rates and requirements upon request.

The editors and publishers do not guarantee, warrant or endorse any product or service advertised in this publication. Neither do they guarantee any claims made by the manufacturer of such product or service.

Submission

Manuscripts, correspondence, and all materials for review and publication should be sent to the Editor-in-Chief of the Journal of Philippine Medical Association at the Editorial Office.

Subscription and advertisements, including change of address should be sent to the PMA Secretariat at 2nd floor PMA Building, North Avenue, Quezon City, 1105 Philippines.

Antimicrobial and Barrier Repair Properties of Virgin Coconut Oil And Mineral Oil in Pediatric Atopic Dermatitis Patients, A Randomized, Double-Blind, Control Trial*

Claudine Joy M. Ramos, MD[1]

ABSTRACT

Background: Atopic dermatitis (AD) is a chronic relapsing skin disease in childhood, managed by topical therapies. In the Philippines, use of affordable, widely available and effective alternative therapies such as mineral oil (MO) and virgin coconut oil (VCO), are practical especially in the far-flung areas.

Objectives: This study compares the antimicrobial and barrier repair properties of MO and VCO in mild to moderate atopic dermatitis, using SCORAD (SCORing for Atopic Dermatitis), bacterial culture, tewameter, mexameter and corneometer.

Methods: This is a randomized controlled double-blind trial conducted in two tertiary hospitals. Bacterial colonies, transepidermal water loss (TEWL), level of hydration and erythema were determined at baseline and after 4 weeks using bacterial culture, tewameter, corneometer and mexameter, respectively. SCORAD and adverse effects were also determined at baseline, 2nd and 4th week of treatment.

Results: Baseline patient demographics were similar for both treatment groups. The SCORAD, TEWL and level of erythema were significantly decreased throughout the 4-week duration for both treatment groups, but much lower in the VCO group. The hydration level was significantly increased throughout the 4-week duration but much higher for the VCO group. Lastly, there is more proportion of cultures with "no growth" after the 4-week treatment duration in VCO group.

Conclusion: The antimicrobial and barrier repair properties of VCO are very important alternative which is affordable, readily available, safe and effective for children with mild to moderate AD.

Key Words: dermatitis, atopic, virgin coconut oil, mineral oil, Philippines

INTRODUCTION

Atopic dermatitis (AD), a common skin disease in childhood, especially in 3-6 months old infants is diagnosed by modified Hanifin major criteria of a history of chronic and relapsing course; pruritus; pattern of facial and extensor eczema and xerosis at a younger age, becoming flexural at adult age; and frequent association with a family history of AD. Approximately 60% of patients develop flares in the first year of life and 90% by 5 years of age.[1]

There is a rapidly increasing AD prevalence trends reported, in the U.S. at 11.3–12.7% and 6.9–7.6% in children and in adults, respectively[2], and in other temperate countries, at 10% to 20% in children, and 3% in adults.[3] Likewise, the 12- month prevalence of AD in the Asia Pacific region in children aged 13 to 14 years is reported at 9% in Malaysia and Singapore. In the Philippines, there is a 47% prevalence of atopic dermatitis from 2011 to 2018 according to the Philippine Dermatological Society – Health Information System as shown in Figure 1.[4]

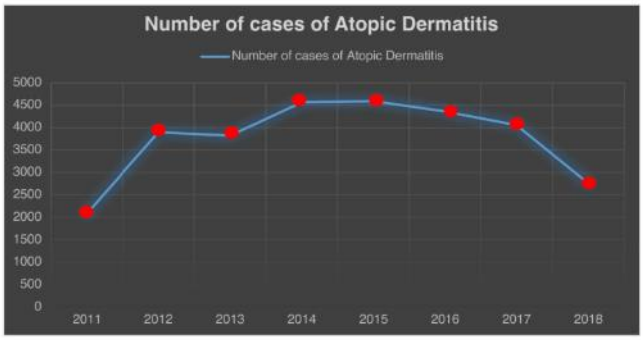

Figure 1. Prevalence of atopic dermatitis from the Philippine Dermatological Society Health Information System (2011-2018)

1st Place, 2020 Philippine Medical Association Original Research Presentation, September 7, 2020

[1]*Resident, Quirino Memorial Medical Center, Quezon City*

On the other hand, the Philippine Pediatric Society reported 1,005 cases from January 2010 to September 2019, mostly seen at NCR (49.55%) as shown in Figure 2.[5]

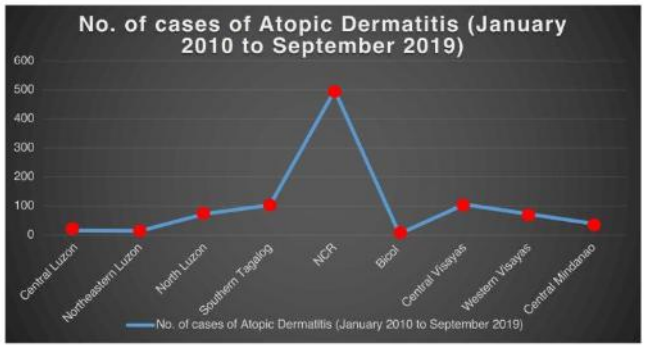

Figure 2. Prevalence of atopic dermatitis from the Philippine Pediatric Society (January 2010 to September 2019)

Management is geared towards the prevention of flares based on current knowledge of its complex pathogenesis.[6] Barrier disruption due to filaggrin deficiency leading to dry skin and inflammation with secondary bacterial infection, are often addressed with the use of topical therapies such as steroids.[7] However, topical steroids are known for its side effects and its absorption especially in children may have greater adverse effects. Moisturizers were used as primary treatment for mild atopic dermatitis and as adjunctive therapy for moderate to severe atopic dermatitis, which are safe for children. Petrolatum and MO were known as the old standard of care for AD. MO mainly acts a humectant because its thin film infiltrates the extracellular domains of the stratum corneum, therefore, the oil smoothens the dry, curled edges and fills the gaps between the desquamating keratinocytes.[8] On the other hand, the traditional topical use[9] and many clinical studies show virgin coconut oil (VCO) to have barrier repair, emollient, occlusive, anti-inflammatory and antibacterial properties[10-11] that have found use in the treatment of AD and xerosis.[12-13] VCO is composed of three fatty acids attached by ester linkages to the carbon atom of glycerin. Glycerin is known to retain water, hence the oil's humectant property.[8] In a study comparing MO and VCO, VCO decreased the mean SCORAD indices by 68.23% from baseline up to 8 weeks as compared to 38.1% decrease in MO. There is also a greater decrease in transepidermal water loss (TEWL) from 26.68 at baseline to 7.09 after 8 weeks in the VCO group as compared with MO group with baseline and post-treatment TEWL values of 24.12 and 13.55, respectively. Lastly, there is a greater increase in skin capacitance in the VCO group from 32.0 at baseline to 42.3 after 8 weeks as compared to the MO group with increase from baseline of 31.31 to 37.49.[14]

The increasing prevalence of AD in the country, with its chronic, unremitting course of intractable pruritus is a great burden that interferes with quality of life not just of the patient[15] but also the entire family.[16] In a developing country like the Philippines, there is a lack of access to health care services and medicines, especially in the far-flung areas. As shown in Figure 2, most of the cases are seen in NCR (49.55%); however, the sum of cases in the provinces is higher (50.45%) than NCR and does not account to under-reported cases. Hence, there is a need for an affordable, widely available and effective alternative therapy. Therefore, this study's primary objective is to compare the antimicrobial and barrier repair properties of VCO and MO in pediatric patients with mild to moderate AD. The specific objectives, is to determine the SCORAD level, TEWL, level of hydration and erythema, as well as antimicrobial properties using tewameter, corneometer, mexameter and bacterial culture, respectively.

MATERIALS AND METHODS

Study Design

This is a two-arm parallel randomized, controlled, double-blind trial comparing the antimicrobial and barrier repair properties of VCO & MO in mild to moderate atopic dermatitis in pediatric patients in two tertiary hospitals.

Population

Patients 18 years old and below coming in for consult or referred to the two tertiary hospitals, who were recently or previously diagnosed with mild to moderate AD based on Hanifin major criteria

were included in the study. Exclusion criteria were grossly infected lesions, other diagnoses aside from AD and use of any topical or oral steroids or antibiotics for at least 2 weeks before enrollment. A certificate of approval from the Hospital Ethics Committee was obtained before the trial was initiated. Informed consent from the parents and assent form for children ≥9 years old were obtained.

Sample Size

The sample size was calculated using a power of 80% and 0.05 level of significance, using the formula for computing the difference between two proportions. The improvement of SCORAD indices of VCO and MO were set at 70% and 40%, respectively, based on another study [14]. The computed sample size was 39 for each study arm.

Interventions

VCO was sourced from FRV USDA-Certified Organic Coconut Farm in Barrio Sto. Nino, Leyte and was manufactured without heat under sterile laboratory conditions that followed standard GMP. On the other hand, commercially available MO from a Philippine drug store was used. The high quality pure oils were sourced and repackaged in uniform medicinal opaque plastic bottles with a small opening to mask the color and scent of both oils. Test bottles were coded (X or Y) by the pharmacist. Patients were given 2 bottles (7mL) of the assigned oil and were instructed to apply and massage 0.5 mL (using 1 cc syringe) to the chosen site twice a day immediately after bathing for 5 to 10 minutes. Application of the assigned oil was done for 2 weeks and were asked to follow up to be given refills. They were given the same mild soap.

Outcomes

At baseline and after 4 weeks treatment, severity, transepidermal water loss (TEWL), level of hydration, and erythema for involved areas were determined using SCORing for Atopic Dermatitis; tewameter, corneometer and mexameter (Courage + Khazaka electronic GmbH Mathias-Bruggen-STR. 91 50829 Köln, Germany), respectively. Baseline photographs were also obtained with consent from the parent and patient.

Swabs were collected from clinically uninfected involved sites that were identified by the investigator, each with an easy to identify anatomic landmark. Starting at the center of the site, cotton swabs soaked with sterile normal saline solution were swept over the chosen site (one swab per site); cotton swabs were submitted to the medical technologist at the microbiology department of a hospital laboratory. After 4 weeks of treatment, cotton swab samples were taken again from the same sites of the first cultures and were sent to the same microbiology laboratory.

Both patient and physician-reported adverse effects were assessed after 2 and 4 weeks of treatment.

Randomization, treatment allocation, and blinding

Recruited patients were randomly allocated to the treatment groups by computer generated random numbers. The assigned test bottle was dispensed by the resident who were blinded to the codes. The codes were not disclosed to the investigators until the end of the study. Patients however, can differentiate VCO from MO through its smell, so they were not blinded and were asked not to disclose their assigned treatment to the investigators nor to the resident.

Statistical Analysis

Descriptive statistics was presented using mean and standard deviation for quantitative data and frequency and proportion for qualitative data. For baseline demographics, independent t test was used to compare quantitative data between the two treatment groups, while Chi-square test was performed to compare qualitative data between two treatment groups, provided that the assumptions of Chi-square test were met. Otherwise, Fisher's exact test was performed.

For the outcome measures, data analysis was done using Two-way repeated measures anova for the quantitative data, with data representation using line graphs. For qualitative data, Chi-square test was performed.

The level of significance was set at p values <0.05. Statistical analysis was done using Stata version 13.

RESULTS

Participant Flow

A total of 80 patients were recruited and enrolled to the study using the inclusion and exclusion criteria from October 2018 to September 2019. 40 patients were allocated for each treatment arm. In between the first and second treatment week, 1 patient from MO group dropped out from the study because the patient had measles. On the other hand, there was no dropout in VCO Group. All patients for each group were analysed and intention to treat analysis was done for the dropout in MO Group using last observation carried forward.

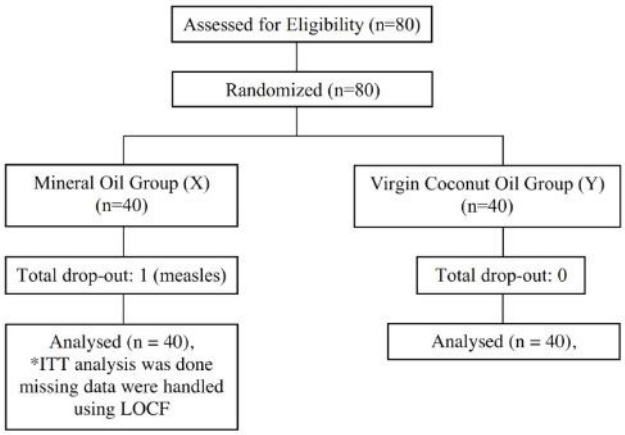

Figure 3. Participant Flow for the Duration of the Study

Patient Demographics

Patient demographics are reported in Table 1. A total of 80 patients were recruited from October 2018 to September 2019. There is no significant difference in the mean age, sex and duration of AD at baseline in between the VCO and MO group. The mean age for patients in the MO and VCO group is 6.8 and 7.25, respectively. There are more females than males, with 55% in the MO and 57.5% in the VCO group. Lastly, all patients were noted to have chronic history of AD with mean of 25.75 and 27.17 months in the MO and VCO respectively. Baseline parameters were also shown in Table 1 with no significant difference between the treatment groups.

Table 1. Baseline Patient Demographics

	Mineral Oil Group (n=40)	Virgin Coconut Oil Group (n=40)	p value
Age (mean, SD)	6.80 (5.19)	7.25 (5.59)	0.71 T test
Sex (number, percent)	F 22 (55%) M 18 (45%)	F 23 (57.5%) M 17 (42.5%)	0.82 Chi-square test
Duration in months (mean, sd)	25.75 (17.39)	27.17 (19.05)	0.73 T test
Baseline SCORAD (mean, sd)	31.12 (4.69)	30.8 (5.42)	0.78 T test
Baseline mexameter erythema (mean, sd)	341.85 (11.40)	317.55 (10.88)	0.13 T test
Baseline tewameter (mean, sd)	26.49 (1.77)	24.45 (1.27)	0.35 T test
Baseline corneometer (mean, sd)	29.40 (1.77)	26.07 (1.33)	0.14 T test
Culture (number, percent)	S. aureus 39 (97.5%) P. aeruginosa 1 (2.5%)	S. aureus 40 (100%) P. aeruginosa 0	>0.9999 Fisher's exact test

SCORAD Index

SCORAD is a standard tool developed by the European Task Force on Atopic Dermatitis to assess the severity of the extent and intensity of lesions and severity of pruritus and sleep loss. A decrease in SCORAD means that there is an improvement in both subjective and objective AD symptoms. There is a significant decrease in mean SCORAD indices for both treatment groups throughout the 4-week study duration (p value of 0.006) as shown in Table 2. Though the mean SCORAD between groups was comparable at baseline, the mean SCORAD at week 4 was significantly different, with VCO Group having significantly lower mean SCORAD than MO Group (Figure 4).

	Baseline	Week 2	Week 4	p value
Mineral Oil Group	31.12 (4.69)	22.65 (6.13)	14.24 (6.85)	Between treatment groups: 0.006
Virgin Coconut Oil Group	30.8 (5.42)	20.4 (4.21)	9.20 (3.94)	
p value	Across time: <0.0001			

Table 2. Mean SCORAD Indices from baseline up to 4 weeks for MO and VCO Group

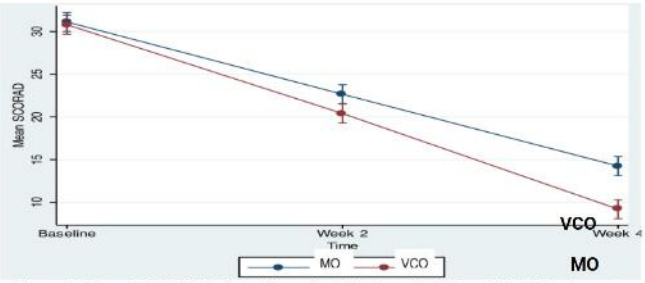

Figure 4. Mean SCORAD Indices throughout the 4-week MO and VCO Treatment

Transepidermal Water Loss (TEWL)

TEWL or insensible water loss is the movement of water from the stratum corneum into the atmosphere, which is significantly increased in AD patients. A decrease in TEWL corresponds to improvement of the skin barrier's function of retaining hydration. There is significant decrease in TEWL as measured by tewameter for both treatment groups throughout the 4-week study duration (p value of 0.04) as shown in Table 3. Though the mean tewameter readings were comparable at baseline, at week 4 they were significantly different, with VCO group having significantly lower mean reading than MO group (Figure 5)

Table 3. Mean tewameter readings from baseline up to 4 weeks for MO and VCO Group

Tewameter (mean, sd)	**Baseline**	**Week 4**	**p value**
Mineral Oil Group	26.49 (1.77)	21.38 (11.38)	Between groups: 0.04
Virgin Coconut Oil Group	24.45 (1.27)	15.31 (3.91)	
p value	Across time: <0.0001		

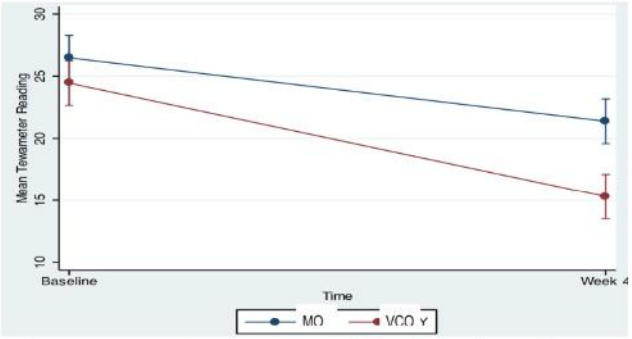

Figure 5. Mean Tewameter readings throughout the 4-week MO and VCO Treatment

Level of Erythema

Erythema is one of the characteristics of the involved areas of the skin in AD and an indicator of inflammation and measured by mexameter. A decrease in the level of erythema is an indicator of improvement with less inflammation. Table 4 shows that the level of erythema is decreased for both treatment groups (p-value 0.01). Though the mean mexameter erythema readings were comparable at baseline, at week 4, they were significantly different, with VCO having significantly lower mean erythema reading than MO (Figure 6).

Table 4. Mean mexameter erythema readings from baseline up to 4 weeks for MO and VCO Group

Mexameter erythema (mean, sd)	**Baseline**	**Week 4**	**p value**
Mineral Oil Group	341.85 (11.40)	307.30 (69.22)	Between groups: 0.01
Virgin Coconut Oil Group	317.55 (10.88)	260.32 (51.02)	
p value	Across time: <0.0001		

Figure 6. Mean Mexameter erythema readings throughout the 4-week MO and VCO Treatment

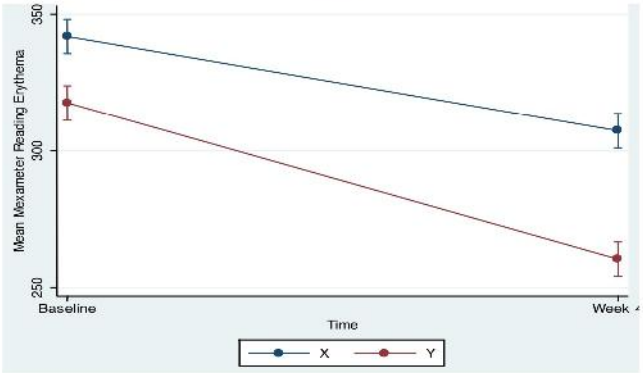

Figure 7. Patient in VCO group at baseline (A) and after 4 weeks treatment (B). Note the significantly decreased erythema after 4 weeks application of VCO

Level of Hydration

Due to impaired skin barrier secondary to filaggrin deficiency, the skin of AD patients were not able to hold moisture, hence, dry. Corneometer measures the hydration level of the stratum corneum, which indicates that the higher the reading, the higher level of hydration. The level of hydration in both treatment groups were significantly increased (p value of 0.88) as shown in Table 6. Moreover, there is significant interaction or change in direction, in that, at baseline, the mean corneometer reading was higher for MO Group, which, at week 4, became lower (Figure 8).

Table 5. Mean corneometer readings from baseline up to 4 weeks for MO and VCO Group

Corneometer Reading	Baseline	Week 4	p value
Mineral Oil Group	29.40 (1.77)	36.05 (7.56)	Between groups: 0.88
Virgin Coconut Oil Group	26.07 (1.33)	39.97 (9.88)	
p value	Across time: <0.0001 Interaction: 0.002		

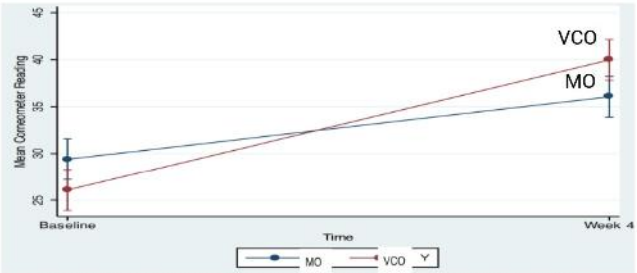

Figure 8. Mean corneometer readings throughout the 4-week MO and VCO Treatment

Bacterial Culture

VCO is currently studied for its antimicrobial effect. The baseline culture was comparable between the two groups, in which most of the patients were positive for *Staphylococcus aureus* colonization. However, one patient in the MO group is positive for *Pseudomonas aeruginosa* colonization. At week 4, there is a significant difference, with significantly higher proportion of subjects with no growth in VCO Group compared with MO Group (Table 6).

Table 6. Bacterial Cultures from baseline up to 4 weeks for MO and VCO Group

	Mineral Oil Group	Virgin Coconut Oil Group	
Week 4 Culture (number, percent)	S. aureus 39 (97.5%) No growth 1 (2.5%)	S. aureus 7 (17.5%) No growth 33 (82.5%)	<0.0001 Chi-square test

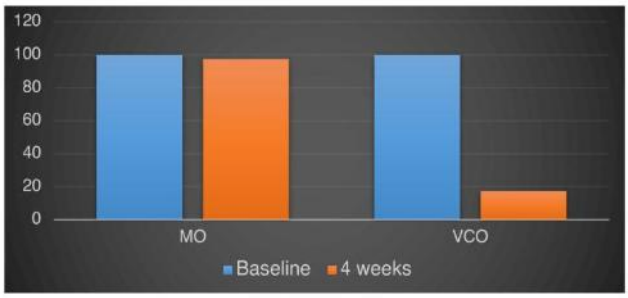

Figure 9. Positive cultures at baseline and after 4 weeks treatment of VCO and MO

Adverse Effects

No adverse effects were reported from both treatment groups

DISCUSSION

The factors that contribute to the complex pathophysiology of AD are genetic predisposition, epidermal barrier disruption, and dysregulation of the immune system. Patients with AD have homozygous mutations in FLG with higher risk of severe AD and earlier onset, longer duration with secondary bacterial infections.[2] Filaggrin is very important in maintaining the barrier and protective function of the stratum corneum minimizing TEWL and minimizing the penetration of foreign antigens. It is also important in maintaining the acidic pH of the skin by releasing free amino acids in the upper stratum corneum, inhibiting bacterial growth.[17]

Immune pathway dysregulation is also important, particularly the T-helper (Th) type 2 signaling pathway, causes increased expression of IL-4 and IL-13 further lowering FLG expression, leading to skin barrier defects.[2] In other studies, both TH type 1 and 2 are involved in the pathogenesis of AD. Environmental and microbial triggers prime an array of antigen presenting cells in the skin causing skin inflammation.[17] Pruritus,

which is a prominent feature of AD is caused by the release of IL-31 which was reported to enhance the release and production of brain-derived natriuretic peptide leading to release of cytokines and chemokines inducing pruritus.

SCORAD index, developed by the European Task Force on Atopic Dermatitis, is a standard tool to evaluate AD which takes into account the extent, intensity of symptoms (erythema, lichenification, excoriation, edema, oozing/crust and dryness) and subjective symptoms of pruritus and sleep loss.[18] This tool also classify AD into mild (SCORAD of 0 - 24), moderate (25 - 50) and severe (>50).[19] It can be also used to monitor improvement after treatment. A decrease in SCORAD throughout the treatment duration, as seen in this study, is an indicator of improvement for both objective and subjective symptoms of AD. This also indicates that the treatment used is effective. This study showed that VCO lowers the SCORAD more significantly than MO, indicating the anti-inflammatory and barrier repair properties of VCO.

TEWL or insensible water loss, is directly associated with the permeability barrier of the skin. This is significantly increased in both the involved and uninvolved areas in AD patients. This barrier defect is the effect of decreased ceramide content in the stratum corneum, which is an important lipid of the intercellular lamellae. Therefore, a decrease in TEWL after treatment, as seen in this study, indicates that the therapeutic management applied is able to repair the barrier defect and retain moisture. This study showed that VCO is more significant than MO in decreasing the TEWL. MO was known to have occlusive effect because of its hydrophobic and non-lamellar palisade, which is able to penetrate intercellularly to prevent water loss, but not completely as compared with VCO. VCO is much better than MO as an occlusive since it is composed of fatty acids (65%) of the same length and 92% are saturated and more compact preventing the evaporation of water from the skin.[11]

Corneometer measures the level of skin hydration by measuring the capacitance of the dielectric medium through the difference between dielectric constant of water and other substances. It is composed of two electrodes with different electrical charges forming an electromagnetic field to determine the dielectric constant of the stratum corneum. Corneometer measurements range from 0 to 130 arbitrary units (AU) and in standard conditions (T°= 20-22°C, humidity 40-60%), values of skin hydration varies from very dry (<30 AU), dry (30 – 45 AU) and sufficiently hydrated (>45 AU).[20] The skin of patients with AD were not able to attract and bind water due to the decreased content of osmotically active amino acids in the keratinocytes. Their skin also has defective lamellae in the stratum corneum which is not able to trap moisture causing decrease in the hydration level.[17] In this study, both treatment arms were noted to have significant increase in the level of hydration, with VCO group having more significant increase than MO. MO is not known to be a humectant, therefore, it is not able to draw moisture from the environment. On the other hand, VCO is composed of triglycerides which is hydrolyzed by lipases when topically applied, becoming free fatty acids and glycerin same as that of the skin composition. Glycerin contains three carbon hydroxyl functional groups which binds with water, absorbing moisture from the environment and the lower layers of the skin, increasing its hydration level.[11] This accounts for the greater increase in corneometer readings for the VCO group as compared with MO group.

Erythema is a prominent feature of the involved areas in AD, indicating the presence of inflammation. Erythema is measured by mexameter by means of two specific wavelengths (green: 568 nm and red: 660 nm), corresponding to the spectral absorption peak of hemoglobin and to avoid other color influences such as bilirubin.[21] Topical treatments that decrease the erythema are ideal for patients with AD. This study showed that both MO and VCO reduced the erythema with more significant reduction in the VCO group. This anti-inflammatory effect of VCO in the skin was studied and results showed that VCO inhibits TNF-α, IFNγ, IL-6, IL-5 and IL-8 with associated improvement in the barrier property of the skin by increasing the expression of AQP-3, filaggrin and involucrin mRNA expression and also by protecting against UVB irradiation[22], hence more significant reduction in the erythema level.

Lastly, bacterial cultures were used to monitor the antimicrobial properties of both arm which showed that the VCO group has higher rates of cultures with no growth compared with the MO group. In patients with atopic dermatitis, the most common bacteria that are present is *Staphylococcus aureus*.[23] The results of the study showed that *Staphylococcus aureus* was 97.5% and 100% isolated by bacterial culture from the MO and VCO groups, respectively. Antibiotic peptides belonging to the dermcidin family in sweat causes *Staphylococcus* colonization in the skin. *Staphylococcus sp.* are speculated to produce exotoxins and lipase that may cause irritation and change the physiologic condition of the skin.[23] VCO is currently being studied for its antimicrobial properties. In a similar study, the antimicrobial property of VCO was compared to virgin olive oil (VOO) and results showed that the VCO group has more significant reduction of 95% in Staphylococcus aureus colonization as compared with VOO (50%). This is attributed to the monolaurin and other medium chain fatty acids present in VCO. The skin's microbiota produces lipases which hydrolyzes the triglycerides in VCO producing 82% medium-chain fatty acids, mostly C-12 (C-6 to C-14) fatty acids, as compared with VOO which is hydrolyzed into long chain fatty acids mostly C-18 (C-16 to C-24, except for 0.1% C-14). Because medium chain fatty acids in VCO are smaller, this allows greater penetration through the bacterial cell membrane and inhibit the enzymes necessary for energy production and transfer of nutrients which leads to irreversible changes that causes bacterial death.[12] Another important product of triglyceride hydrolysis is monolaurin which is a monoglyceride from lauric acid and comprises 50% of the VCO fat content. In studies, monolaurin is known to penetrate the lipid membranes of the bacteria such as *Propionibacterium acnes*, *Staphylococcus aureus*, and *Staphylococcus epidermidis* causing bacterial death.[24]

These antimicrobial and barrier repair properties shown by VCO is a very important treatment strategy for children with mild to moderate AD. VCO provides an affordable, readily available, safe and effective treatment for children with AD with less side effects.

LIMITATIONS AND RECOMMENDATIONS

There are two limitations of this study that could be further addressed in future studies. First is that the study is conducted for a 4-week treatment duration. Future studies may extend the duration to 8 weeks to see the results after longer application of the oils. Another limitation is that the microbiologic cultures are qualitative with no colony forming units. This is because the medical technologists of the hospital laboratory cannot measure the colony forming unit of the culture. Providing the colony forming units may further express the decrease in the number of bacterial colonies after treatment.

CONCLUSION

The antimicrobial and barrier repair properties of VCO are very important alternative which is affordable, readily available, safe and effective for children with mild to moderate AD.

REFERENCES

1. GOLDSMITH, L. A. Atopic Dermatitis. Fitzpatrick's Dermatology in General Medicine Eighth Edition. McGraw Hills Companies, Inc. 2012

2. Kim J, Kim BE, Leung DYM. Pathophysiology of atopic dermatitis: Clinical implications. Allergy Asthma Proc. 2019;40(2):84–92. doi:10.2500/aap.2019.40.4202

3. Barbarot, S., Auziere, S., Gadkari, A., Girolomoni, G., Puig, L. Epidemiology of Atopic Dermatitis in adults: Results from an International Survey. 2018

4. Philippine Dermatological Society Health Information Systems. Philippine Dermatological Society. c2011 [updated (August 22, 2019); cited (September 5, 2019)]. Available by request from: pdshis@outlook.com

5. Search for Disease and its ICD [Internet]. Philippine Pediatric Society [cited 2019 Sept 12]. Available from: http://pps.ivant.com/search.do?fbclid=IwAR3yPQRmrGTok3igmSCnwlqcc8Yupt7VRcyGFvXVTRiv1di5hGfbk_fE13s

6. Eichenfield LF, Ahluwalia J, Waldman A, Borok J, Udkoff J, Boguniewicz. Current guidelines for the evaluation and management of atopic dermatitis: A comparison of the Joint Task Force Practice

Parameter and American Academy of Dermatology guidelines (2017). American Academy of Allergy, Asthma & Immunology

7. Zaniboni MC, Samorano LP, Orfali RL, Aoki V. An Bras Dermatol. Skin barrier in atopic dermatitis : beyond filaggrin. 2016 Jul-Aug;91(4):472-8. doi: 10.1590/abd1806-4841.20164412. Review. PMID: 27579743

8. Rawlings, A. V. and K. J. Lombard. A review on the extensive skin benefits of mineral oil (2012). International Journal of Cosmetic Science, 2012, 34, 511–518

9. Divina D. Bawalan BSChE, M. (n.d.). Processing Manual for Virgin Coconut Oil, its Products and By-products for Pacific Island Countries and Territories.

10. Verallo-Rowell VM, Katalbas S S, Evangelista MTP, Dayrit J. Review update on Topical Therapy for psoriasis in Current Dermatology Reports, Springer 2018 Mar; 7(1):24-36.

11. Verallo-Rowell VM, Katalbas SS, Pangasinan JP. Natural (Mineral, Vegetable, Coconut, Essential) Oils & Contact Dermatitis. Curr Allergy Asthma Reports Jul 2016; 16(7):51 https://doi.org/10.1007/s11882-016-0630-9

12. Verallo-Rowell VM, Dillague K, Syah-Tjundawan BS. Novel Antibacterial & Emollient Effects of Coconut & Virgin Olive Oils in Adult Atopic Dermatitis. Dermatitis Nov-Dec 2008;19(6):308-15.

13. Agero AL, Verallo-Rowell VM.A Randomized Double -Blind Controlled Trial Comparing Extra Virgin Coconut w/ Mineral Oil as Moisturiser for Mild to Moderate Xeroxis. Dermatitis 2004 Sept; 15(3):109-16

14. Evangelista, Mara Therese Padilla, MD, Flordeliz Abad-Casintahan, MD, and Lillian Lopez-Villafuerte, MD. The effect of topical virgin coconut oil on SCORAD index, transepidermal water loss, and skin capacitance in mild to moderate pediatric atopic dermatitis: a randomized, double- blind, clinical trial (2014). International Journal of Dermatology 2014, 53, 100–108

15. Odhiambo JA, Williams HC, Clayton TO, Robertson CF, Asher MI, Group IPTS Global variations in prevalence of eczema symptoms in children from ISAAC Phase Three. J Allergy Clin Immunol. 2009;124:1251–1258. e23. [PubMed]

16. Meni, C. C.-C. (2013). Atopic dermatitis burden scale: creation of a specific burden questionnaire for families.

17. Agrawal R, Woodfolk JA. Skin barrier defects in atopic dermatitis. Curr Allergy Asthma Rep. 2014;14(5):433. doi:10.1007/s11882-014-0433-9

18. Dermatology in 1993; 186(1): 23-31 Consensus Report of the European Task Force on Atopic Dermatitis.

19. Marjolein G. Willemsen, Rosalinda W. C. van Valburg, Pauline C. Dirven-Meijer, Arnold P. Oranje, Johannes C. van der Wouden, and Heleen Moed, "Determining the Severity of Atopic Dermatitis in Children Presenting in General Practice: An Easy and Fast Method," Dermatology Research and Practice, vol. 2009, Article ID 357046, 5 pages, 2009. https://doi.org/10.1155/2009/357046.

20. Constantin MM, Poenaru E, Poenaru C, Constantin T. Skin Hydration Assessment through Modern Non-Invasive Bioengineering Technologies. Maedica(Buchar). 2014;9(1):33–38.

21. B. Nedelec, N.J. Forget, T. Hurtubise, S. Cimino, F. de Muszka, A. Legault, W.L. Liu, A. de Oliveira, V. Calva, J.A. Correa, Skin characteristics: normative data for elasticity, erythema, melanin, and thickness at 16 different anatomical locations, Skin Research and Technology 2016; 22: 263-275

22. Varma SR, Sivaprakasam TO, Arumugam I, et al. In vitro anti-inflammatory and skin protective properties of Virgin coconut oil. J Tradit Complement Med. 2018;9(1):5–14. Published 2018 Jan 17. doi:10.1016/ j.jtcme.2017.06.012

23. Dekio, Itaru & Sakamoto, Mitsuo & Hayashi, Hidenori & Amagai, Masayuki & Suematsu, Makoto & Benno, Yoshimi. (2007). Characterization of skin microbiota in patients with atopic dermatitis and in normal subjects using 16S rRNA gene-based comprehensive analysis. Journal of medical microbiology. 56. 1675-1683. 10.1099/jmm.0.47268-0.

24. Lin TK, Zhong L, Santiago JL. Anti-Inflammatory and Skin Barrier Repair Effects of Topical Application of Some Plant Oils. Int J Mol Sci. 2017;19(1):70. Published 2017 Dec 27. doi:10.3390/ijms19010070

Computer-Aided Detection Of Pulmonary Tuberculosis and Pulmonary Cavity on Adult Chest Radiographs using a Region Convolutional Neural Network*

Kevin Eric R. Santos, MD[1]

ABSTRACT

Objectives: To train and evaluate the performance of a detector for pulmonary tuberculosis and pulmonary cavity, using the Faster Region Convolutional Neural Network model.

Methods

Study Design: A cross-sectional study design was employed to describe the sensitivity, specificity, and accuracy of the Faster Region Convolutional Neural Network model for the detection of pulmonary tuberculosis and pulmonary cavity.

Subjects: Radiographs for the training dataset and testing dataset were acquired from the Picture Archiving and Communication System of the a general public hospital in Quezon City.

Setting: The setting of the study is a general public hospital in Quezon City, Philippines.

Outcomes: The detector for pulmonary tuberculosis and pulmonary cavity was trained with the training dataset using the TensorFlow machine learning library, with the Faster-RCNN-Inception-V2 used as the base model.

Detector findings on the testing dataset were compared and analyzed against findings of three board-certified radiologists.

Results: The detector achieved 92.11% sensitivity, 87.1% specificity, and 89% accuracy as a screening tool, and 84.04% sensitivity, 98.04% specificity, and 95.87% accuracy, as a locator of pulmonary tuberculosis and cavity.

Conclusion: This study is the first of its kind to demonstrate the feasibility of training a detector for pulmonary tuberculosis and pulmonary cavities using the Region Convolutional Neural Network model. Limitations and improvements to the detector may be addressed in future research.

Keywords: Tuberculosis, Pulmonary, Sensitivity and Specificity, Neural Networks (Computer), Software

INTRODUCTION

Pulmonary tuberculosis (PTB) remains one of the illnesses with high disease burden in the Philippines. According to the 2016 National Tuberculosis Prevalence Survey, the prevalence of PTB in the Philippines is 10.6 per 1000 persons, which is an increase from the previously measured prevalence of 4.7 per 1000 persons in 2007 [1]. Radiology plays a vital role in the diagnosis of the disease. The chest radiograph and sputum smear and culture are the initial diagnostic tests for patients suspected of PTB.

Several studies on computer-aided detection of PTB on chest radiographs have been published. CAD4TB by Delft Imaging Systems, is the only commercial software package on the market for computer-aided detection of PTB. A systematic review investigating 5 studies on the software, showed that CAD4TB demonstrates middle to high sensitivity (47-100%), and inconsistent specificity (23-94%). Concerns were raised regarding the generalizability of the software to populations other than those used to train it. The review concludes that evidence to support the use of computer-aided detection in PTB diagnosis is limited and that more research in the field is needed. [2] In recent years, the convolutional neural network (CNN) has been the

*2nd Place, 2020 Philippine Medical Association Original Research Presentation, September 7, 2020

[1]Resident, Quirino Memorial Medical Center, Quezon city

most successful computational algorithm used in computer vision research.[3] Two studies were published applying a CNN to PTB detection. Research by Hwang et al. in 2016 pioneered the use of a CNN in detecting PTB and achieved an area-under-curve (AUC) of 0.964[4]. A similar study by Lakhani et al. in 2017, demonstrated a higher AUC of 0.99, with 97% sensitivity and 100% specificity[5]. The limitation of using CNN is that it can accurately classify PTB, but cannot explicitly point out the location of the disease. The Region Convolutional Neural Network (R-CNN) is an algorithm derived from CNN capable of identifying the location of the object of interest within a larger image. Several iterations on the R-CNN algorithm have been developed, namely the Fast R-CNN and the Faster R-CNN. The latest iteration of this algorithm is the Faster R-CNN, which is as accurate, but is capable of detection at higher speed than earlier versions.[6]

The objectives of this study are: 1) to train a detector for PTB opacities and pulmonary cavity based on the Faster R-CNN model, and 2) to test the sensitivity, specificity, and percent accuracy of the detector as a screening tool and as a locator for PTB opacities and pulmonary cavities.

SIGNIFICANCE OF THE STUDY

While researches were published exploring the application of CNN in PTB detection, no study yet exists on the application of R-CNN to the problem of PTB detection.

In addition to bridging this gap in knowledge, there are also other compelling reasons to conduct research in the field of computer-aided detection in medical imaging. Novel systems need to be assessed for sensitivity, specificity, and accuracy. Off-the-shelf commercial software for PTB detection are expensive and may not be applicable to the local population, hence the need to create detectors trained with radiographs of the local population.

Development of such software may be integrated into public health screening programs for PTB, and may be utilized in areas where radiologists are unavailable.

MATERIALS AND METHODS

The methodology of this study proceeds in two phases:

1. Training the Faster R-CNN based classifier for detection of PTB and pulmonary cavities. (see Figure 1)
2. Verification of detector findings, against the findings of a panel of 3 board certified radiologists. (see Figure 2)

Training the Faster R-CNN based detector

Systematic search for chest radiographs with PTB and pulmonary cavities

A systematic search through official results of chest radiographs done in a general public hospital in Quezon City, from January 2016 to January 2018 was performed. Search terms used were "PTB", "cavity", "cavitation" and "cavitary". This yielded an initial pool of 816 radiographs.

Inclusion and exclusion criteria were applied, after which only 654 radiographs were included. Only initial chest radiographs of adults 19 years old and above, taken in an upright or sitting position in either anteroposterior or posteroanterior views, were included, while radiographs with medical devices superimposing the lung parenchyma such as electrodes, wires, tubes and catheters, were excluded.

Collection, processing and annotation of sample chest radiographs

The 654 chest radiographs included in the study were downloaded from the picture archiving and communications system (PACS) in Digital Imaging and Communications in Medicine (DICOM) format. Age, sex, hospital number, and accession number of the radiographs were encoded. Names of patients were removed, anonymizing the dataset. These were then converted to jpeg files with the program MicroDicom viewer[7].

Histogram equalization and reduction in size to 600 pixels height, with aspect ratio

maintained for image width, were performed with the software GIMP 2.10.8[8].

Out of the 654 images, 100 images were randomly selected and set aside to form part of the testing dataset. Random selection was done with Microsoft Excel, by assigning pseudorandom numbers to each radiograph via the *rand()* function and sorting the radiographs in an ascending manner based on the generated pseudorandom numbers. The first 100 radiographs with the smallest pseudorandom numbers were selected and set aside for testing, while the remaining 554 images would comprise the training dataset.

The images in the training dataset were then annotated with the program LabelImg[9]. Bounding boxes were placed around findings of PTB opacities and pulmonary cavities, based on the text of the official result of each radiograph.

Training the PTB and cavity detector

The images were loaded onto a computer with the following specifications: Windows 7 64-bit operating system, Intel Core i7-6700 CPU, 1TB of hard disk space, and 8GB of RAM.

Training process and source code used for training were adapted from the process described by Juras[10], which used the object detection module of the open source machine learning library, TensorFlow. The Faster-RCNN-Inception-V2 was used as the base model.

The detector was trained with the 554 training images for 38 epochs.

Testing the PTB and cavity detector

Overview of testing methodology

The PTB and cavity detector was tested on a randomized set of radiographs composed of approximately one-third radiographs with PTB and/or cavity, one-third radiographs with pathology other than PTB and cavity, and one-third negative chest radiographs. The findings of the detector were then verified by a panel of three board-certified radiologists.

Sample size calculation

Sample size calculation for the number of testing radiographs was determined using the tables for minimum sample size for sensitivity and specificity analysis, as determined by Bujang[11] (see Appendix 1). Minimum sample size was 67 test radiographs using parameters of 30% prevalence, minimum sensitivity of 80%, and 80% power.

Preparation and randomization of test images

A systematic search through official results of chest radiographs done in a general public hospital in Quezon City from January 2016 to January 2018 was performed for 1) negative chest radiographs and 2) pathologic chest radiographs without PTB and cavity. This initial search yielded 10,000 results for each category.

One hundred radiographs from each category were randomly selected using the previously described randomization process using Microsoft Excel. These were downloaded from the PACS as DICOM format and processed in the same manner as radiographs in the training dataset.

These were pooled with the 100 radiographs with PTB and pulmonary cavity set aside previously. From this pool of 300 chest radiographs, 100 radiographs were randomly selected, using the same randomization process.

The final set of test images is a heterogeneous set of 100 radiographs composed of 32 radiographs with PTB and/or cavity, 36 negative chest radiographs, and 32 pathologic non-PTB non-cavity chest radiographs. Pathologic non-PTB non-cavity radiographs comprise a myriad of pathologies, such as pneumonia, pleural effusion, bronchitis/bronchiectasis, pulmonary congestion, fibrosis, subsegmental atelectasis, and fibrosis (see Table 1).

Application of the detector to the test images

The detector was then applied to the test images, using the object detection module within TensorFlow. Coordinates of bounding boxes representing areas with PTB and cavity were

determined by the detector, and were drawn onto the image file using the module OpenCV[12], producing the final output images (see Figure 3).

Verification of detector findings

Verification of the detector findings was performed by three board-certified radiologists of the Philippine College of Radiology, each with 5-6 years of training and experience in radiology. Each radiologist was given the set of final output images, and a verification sheet with the list of findings per image (see Appendix 2). Each finding was then verified as either true or false. In addition, the verifying radiologist was asked to note any missed PTB opacities or cavity. For each finding, at least 2 out of 3 verifying radiologists must be in agreement to be valid.

Each bounding box was classified into one of the following categories:

- True negative finding - The detector did not identify any finding, confirmed by the verifying radiologists.
- True positive finding - The detector identified a PTB opacity or cavity, confirmed by the verifying radiologists.
- False negative finding - The detector did not identify any finding on the radiograph, but verifying radiologists identified a missed PTB opacity or cavity.
- False positive finding - The detector identified a PTB opacity or cavity, but verifying radiologists disagreed with the finding.

Data Analysis

The results of verification were analyzed in two different ways, in accordance with the study objectives.

First, the data was analyzed as a screening tool for PTB, utilizing the chest radiograph as the unit of analysis, and making use of lenient parameters for classification. Each chest radiograph in the final set of test images was classified into one of the following categories (see Figure 4):

- True Negative Radiograph - The radiograph contains no findings.
- True Positive Radiograph - The radiograph contains at least one true positive finding. If false positive and false negative findings are also present, the radiograph is still counted as a true positive.
- False Negative Radiograph - The radiograph contains at least one false negative finding.
- False Positive Radiograph - The radiograph contains at least one false positive finding. If there is also a false negative finding, the radiograph is still classified as a false positive.

Second, the data was analyzed as to its performance in locating PTB opacities and cavities on chest radiographs. The lungs on each radiograph were divided into 6 parts based on location and laterality, into upper, middle, and lower lungs on the left or the right. Each one-sixth region formed the unit of analysis for analysis as locator. Bounding boxes are determined to be within the lung region if greater than 50% of the box area is within the lung region.

Each one-sixth portion were classified as follows, based on radiologist verification (see Figure 5 for examples):

- True Negative Lung Region - The lung region contains no findings.
- True Positive Lung Region- The lung region contains at least one true positive finding.
- False Negative Lung Region - The lung region contains a missed PTB opacity or cavity.
- False Positive Lung Region - The lung region contains a finding verified to be a false positive.

If a region is classified into two or more groups, it will be classified by the largest box by

area. If a finding is detected outside the bounds of the lungs, it is counted as an additional false positive.

After classification, 2x2 contingency tables were used to derive sensitivity, specificity, and accuracy.

RESULTS

As a screening tool, the trained detector for PTB opacities and pulmonary cavity demonstrated 92.11% sensitivity, 87.1% specificity, and 89% overall diagnostic accuracy . (see Table 2 and 3)
As a locator of PTB opacities and pulmonary cavity, the trained detector demonstrated 84.04% sensitivity, 98.04% specificity, and 95% overall diagnostic accuracy. (see Table 4 and 5)

DISCUSSION

The trained detector performed better as a screening tool than a locator, achieving 92.11% sensitivity and 87.11% specificity. This is due to the fact that all radiographs with a true positive finding, whether there were also false positives and false negatives within the same radiograph, were counted as true positive. This parameter was made more lenient to maximize sensitivity, which is the goal of a screening tool.

In comparison, analysis of the detector as a locator showed slightly lower sensitivity of 84.04%, while specificity was higher at 98.04%. There were significantly more false negatives in this analysis. This meant that the detector failed to recognize certain opacity configurations (see Figure 6), thereby decreasing sensitivity. On the other hand, specificity was markedly increased to 98.04%. This can be attributed to increased representation of areas with negative findings, due to the shift to the unit of analysis to the one-sixth lung region. This amplified the true negative regions to a total of 501, increasing specificity.

There were few reasons for false positive findings (see Figure 7). Some false positives were due to the detector mistaking other lung opacities, such as pneumonia or pulmonary congestion, for PTB. Another common source of false positives was the stomach bubble being mistaken for a PTB opacity or cavity.

As a screening tool, the trained detector may only be compared to other studies that used algorithms for image classification (see Table 6). In comparison with studies utilizing histogram analysis, the trained detector was mostly at par in terms of sensitivity, exhibiting slightly lower sensitivity than that by Rohmah et al., which had a sensitivity of 93.3%, but exhibiting slightly higher sensitivity than that by Tan et al., which had a sensitivity of 91%.

In comparison with studies utilizing CNN, the detector was only slightly less accurate than that by Hwang et al., which achieved 90.3% accuracy as opposed to this study's accuracy of 89%. However it was markedly less sensitive and specific than that by Lakhani et al., which had a sensitivity and specificity of 97.3% and 100%, respectively. This may be attributed to a smaller number of training samples used in this study, as compared to these studies. The study by Hwang utilized 7500 images, while the study by Lakhani used 1016 images, as opposed to the 554 used in this study.

Compared with the above-mentioned studies which used histogram analysis or CNN, the trained detector had lower specificity and accuracy across all studies, regardless of algorithm (see Table 6). This may be attributed to the fact that, aside from Rohmah et al., other studies used only either normal chest radiographs or radiographs with PTB in their testing dataset. In contrast, this study incorporated radiographs with other pathologic findings such as pneumonia or congestion in the testing phase. This caused more false negatives, with the detector mistaking other opacities for PTB. However, this approach is more reflective of real-world situations.

Pande et al[2] cited 8 studies in total pertaining to CAD4TB. The detector in this study demonstrated greater sensitivity than 6 of 8 studies, and greater specificity than 7 of 8 studies (see Table 6).

The study by Xu et al., which utilized a combination of Gaussian-model-based template matching (GTM), local binary patterns (LBP), and histogram of oriented gradients (HOG), is the only other published research that also attempted location of PTB opacities. As a locator, the trained detector in this study had markedly higher sensitivity, specificity, and accuracy than that by Xu et al (see Table 7). This may be attributed to higher number of training samples. Xu et al. only used 30 training samples, as opposed this study which utilized 554 training samples. Another reason for better performance may be due to the Faster R-CNN algorithm being more robust in object detection than GTM, LBP, and HOG.

Some studies such as that by Hwang et al., Lakhani et al., and Pande et al., incorporated a microbiologic basis for PTB in their studies. A limitation and weakness of this study is the lack of any microbiologic basis.

CONCLUSION AND RECOMMENDATIONS

This study has demonstrated the feasibility of training a detector for PTB and pulmonary cavities using the Faster R-CNN algorithm. Performance in terms of sensitivity, specificity and accuracy were comparable to and exceeded that of similar studies, and even that of commercially available software.

This study is the first of its kind to utilize Faster R-CNN in the detection of PTB opacities and pulmonary cavities. Faster R-CNN is a general object detection algorithm, and this study may be used as a template for the creation and assessment of detectors for other findings on medical images.

Performance of the detector may be improved by incorporating the following in future research:

- The number of training images may be increased to increase the variety of findings that the detector is exposed. This may decrease the number of false negative findings.
- The Faster R-CNN algorithm may be combined with a lung segmentation algorithm to prevent out-of-bounds findings. This may decrease the number of false positive findings.
- Using a microbiologic basis for establishing PTB along with chest radiographs would increase research validity.

REFERENCES

1. 2016 National Tuberculosis Prevalence Survey Results [Internet]. 24th Annual PhilCAT Convention; Philippine Coalition Against Tuberculosis; 2017 Aug 17; Crowne Plaza, Robinsons Galleria, Ortigas Center, Quezon City, Philippines. Available from: http://www.philcat.org/PDFFiles/2.NTPSPhilCAT_17Aug2017_Dr.%20Lansang.pdf
2. Pande T, Cohen C, Pai M, Ahmad Khan F. Computer-aided detection of pulmonary tuberculosis on digital chest radiographs: a systematic review. Int J Tuberc Lung Dis. 2016;20(9):1226–30.
3. Von Zitzewitz G. Survey of neural networks in autonomous driving. 2017 Jul 9 [cited 2019 Jun 22]; Available from: http://dx.doi.org/
4. Hwang S, Kim H-E, Jeong J, Kim H-J. A novel approach for tuberculosis screening based on deep convolutional neural networks. In: Medical Imaging 2016: Computer-Aided Diagnosis [Internet]. 2016. Available from: http://dx.doi.org/10.1117/12.2216198
5. Lakhani P, Sundaram B. Deep Learning at Chest Radiography: Automated Classification of Pulmonary Tuberculosis by Using Convolutional Neural Networks. Radiology. 2017 Aug;284(2):574–82.
6. Ren S, He K, Girshick R, Sun J. Faster R-CNN: Towards Real-Time Object Detection with Region Proposal Networks [Internet]. 2015 [cited 2019 Mar 6]. Available from: http://arxiv.org/abs/1506.01497
7. MicroDicom - Free DICOM viewer and software [Internet]. [cited 2019 Mar 7]. Available from: http://www.microdicom.com/
8. GIMP [Internet]. GIMP. [cited 2019 Mar 7]. Available from: https://www.gimp.org/

9. tzutalin. tzutalin/labelImg [Internet]. GitHub. [cited 2019 Mar 7]. Available from: https://github.com/tzutalin/labelImg

10. Evan Juras. How to train a TensorFlow Object Detection Classifier for multiple object detection on Windows [Internet]. Github; 2018 [cited 2019 Mar 9]. Available from: https://github.com/EdjeElectronics/TensorFlow-Object-Detection-API-Tutorial-Train-Multiple-Objects-Windows-10

11. Mohamad Adam Bujang THA. Requirements for Minimum Sample Size for Sensitivity and Specificity Analysis. J Clin Diagn Res. 2016 Oct;10(10):YE01.

12. OpenCV library [Internet]. [cited 2019 Mar 10]. Available from: https://opencv.org/

13. Rohmah RN, Susanto A, Soesanti I. Lung tuberculosis identification based on statistical feature of thoracic X-ray [Internet]. 2013 International Conference on QiR. 2013. Available from: http://dx.doi.org/10.1109/qir.2013.6632528

14. Tan JH, Acharya UR, Tan C, Abraham KT, Lim CM. Computer-assisted diagnosis of tuberculosis: a first order statistical approach to chest radiograph. J Med Syst. 2012 Oct;36(5):2751–9.

15. Maduskar P, Muyoyeta M, Ayles H, Hogeweg L, Peters-Bax L, van Ginneken B. Detection of tuberculosis using digital chest radiography: automated reading vs. interpretation by clinical officers. Int J Tuberc Lung Dis. 2013 Dec;17(12):1613–20.

16. Breuninger M, van Ginneken B, Philipsen RHHM, Mhimbira F, Hella JJ, Lwilla F, et al. Diagnostic accuracy of computer-aided detection of pulmonary tuberculosis in chest radiographs: a validation study from sub-Saharan Africa. PLoS One. 2014 Sep 5;9(9):e106381.

17. Xu T, Cheng I, Long R, Mandal M. Novel coarse-to-fine dual scale technique for tuberculosis cavity detection in chest radiographs [Internet]. Vol. 2013, EURASIP Journal on Image and Video Processing. 2013. Available from: http://dx.doi.org/10.1186/1687-5281-2013-3

APPENDICES, TABLES AND FIGURES

Appendices

Appendix 1. Table for minimum sample size for sensitivity and specificity analysis[11]

Part of the table for minimum sample size for sensitivity and specificity analysis by Bujang[11] is displayed below. The parameters used in this study are boxed in orange.

n (Sensitivity)						
Prev	H_0	H_a	Power	p-value	N1	N
30%	0.50	0.60	0.804	0.047	199	663
30%	0.50	0.70	0.810	0.044	49	163
30%	0.50	0.80	0.804	0.041	20	67
30%	0.50	0.90	0.889	0.039	12	40
30%	0.60	0.70	0.801	0.048	181	603
30%	0.60	0.80	0.826	0.034	45	150
30%	0.60	0.90	0.885	0.035	19	63

n (Specificity)						
Parv	H_0	H_a	Power	p-value	N1	N
30%	0.50	0.60	0.804	0.047	85	284
30%	0.50	0.70	0.810	0.044	21	70
30%	0.50	0.80	0.804	0.041	9	29
30%	0.50	0.90	0.889	0.039	5	17
30%	0.60	0.70	0.801	0.048	78	259
30%	0.60	0.80	0.826	0.034	19	64
30%	0.60	0.90	0.885	0.035	8	27

Appendix 2. Sample of verification log sheet.

Verification Logsheet
Computer-aided detection of PTB and pulmonary cavities on adult chest radiographs

Filename	Finding	Top y	Top x	Bottom y	Bottom x	%	Verification by Radiologist	Missed TB or cavity? Please specify location	Classification - to be filled up by investigator (TP, FP, TN, FP)
test001	No cavity or PTB						/		TN
test002	No cavity or PTB						/		TN
test003	No cavity or PTB						/		TN
test004	No cavity or PTB						/		TN
test005	PTB	216	312	296	384	100.00%	/		TP
	PTB	106	128	198	210	100.00%	/		TP
	PTB	213	307	325	396	99.89%	/		TP
	PTB	109	70	286	221	96.53%	/		TP
	PTB	185	337	244	387	88.47%	/		TP
test006	No cavity or PTB						/		TN
test007	No cavity or PTB						/		TN
test008	No cavity or PTB						/		TN
test009	No cavity or PTB						/		TN
test010	PTB	108	76	195	158	99.98%	/		TP
	PTB	260	102	322	161	99.98%	/		TP

Figures

Figure 1. Flow diagram for training the Faster R-CNN detector

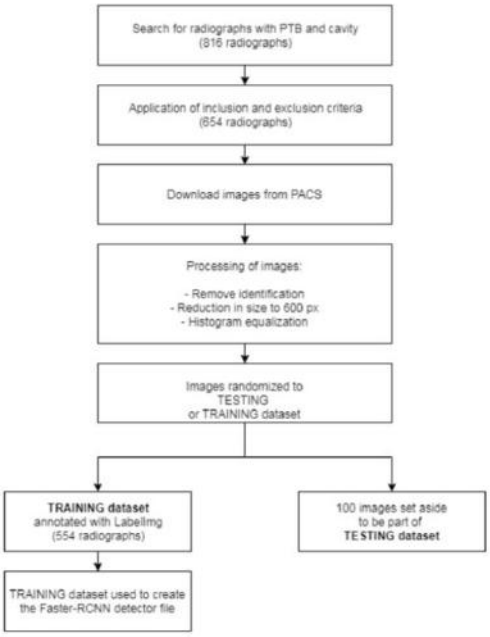

Figure 2. Flow diagram for testing the Faster R-CNN detector

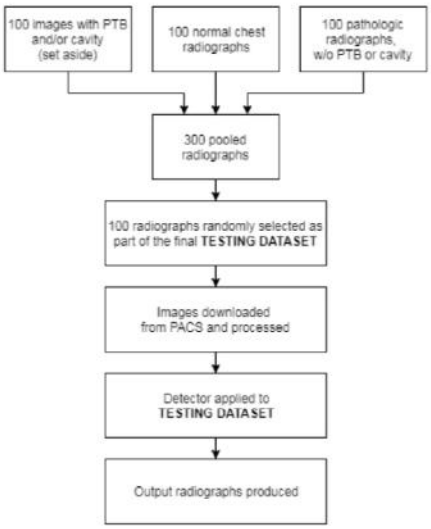

Figure 3. Sample output radiographs demonstrating detection of PTB opacities and cavities.
Each of the output radiographs below show correct detection of PTB opacities (boxed in green) and pulmonary cavities (boxed in yellow).

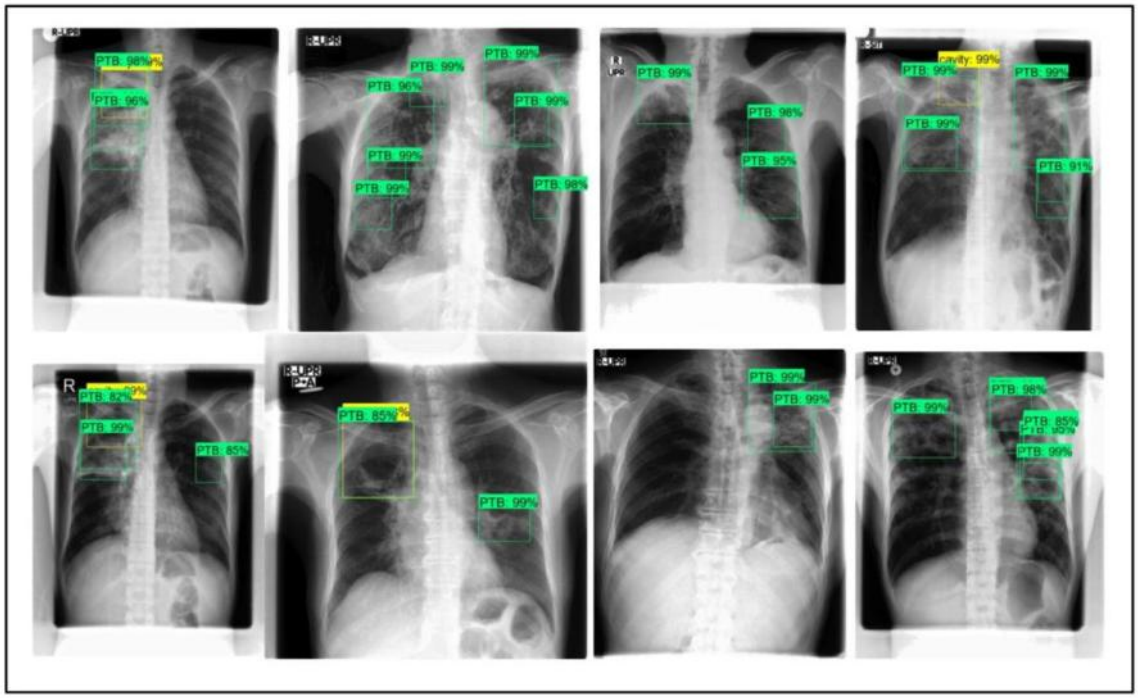

Figure 4. Example radiographs for classifications for analysis as a screening tool.
(In order of images from the left)
1st image: True Negative radiograph shows no identified PTB opacities or cavity.
2nd image: True Positive radiograph shows PTB opacities correctly identified by the detector.
3rd image: False Negative radiograph shows missed PTB opacities (encircled in red) in the right upper lung, which was not identified by the detector.
4th image: False Positive radiograph shows the stomach bubble misidentified as PTB opacity.

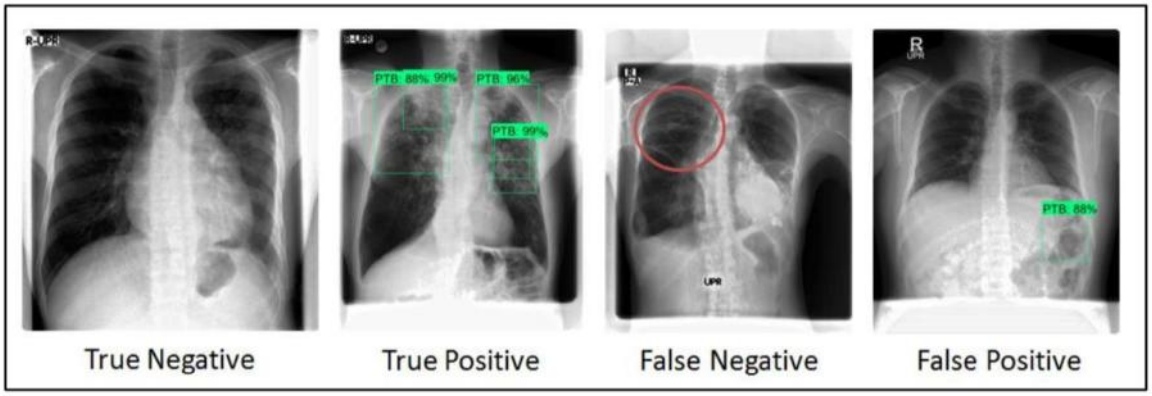

Figure 5. Sample radiograph for classification for analysis as a locator.

The radiograph on the left shows PTB opacities, as identified by the detector. The radiograph on the right shows the same radiograph with blue translucent overlay dividing each lung into upper, middle, and lower regions. Each lung region is classified according to the bounding boxes within it. In this example, bounding boxes are seen occupying the both upper to mid lungs, and are hence classified as true positives. Lower lungs have no bounding boxes, and are classified as true negatives.

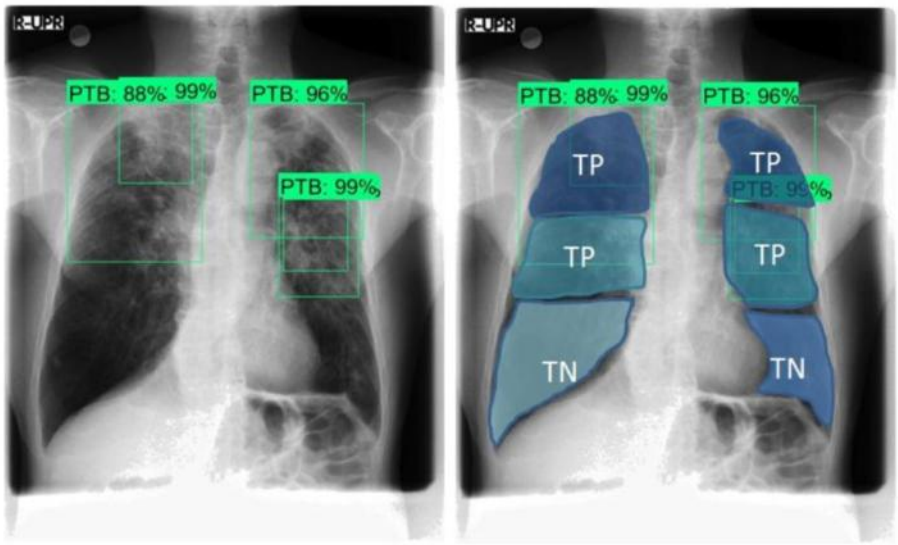

Figure 6. Sample radiographs exhibiting false negatives.

The radiograph on the left exhibits PTB opacities in the right upper lung. The radiograph on the right shows subtle PTB opacities in both upper lungs. The trained detector did not place any bounding boxes around these findings, and were thus considered missed by the detector.

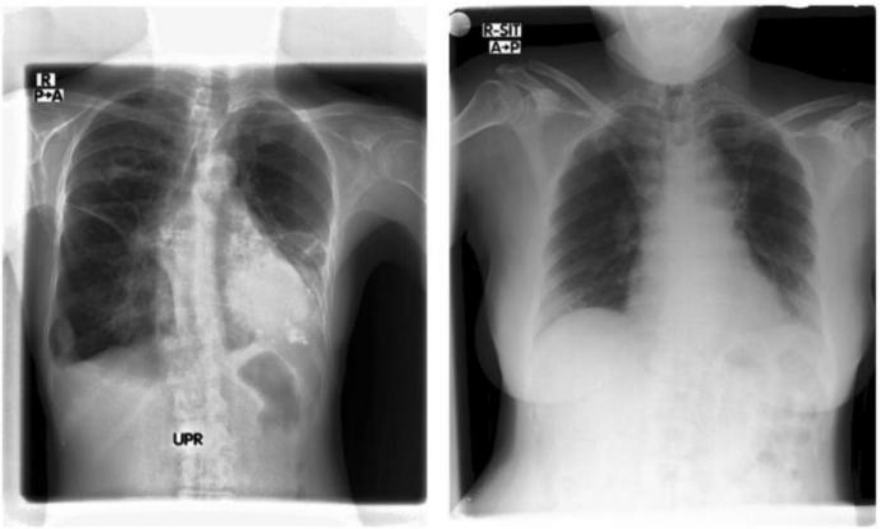

Figure 7. Sample radiographs exhibiting false positives.

Left radiograph: Radiograph exhibits pneumonia mistaken for PTB by the detector.
Middle and right radiographs: Radiographs show the stomach bubble as mistaken for PTB and cavity, respectively.

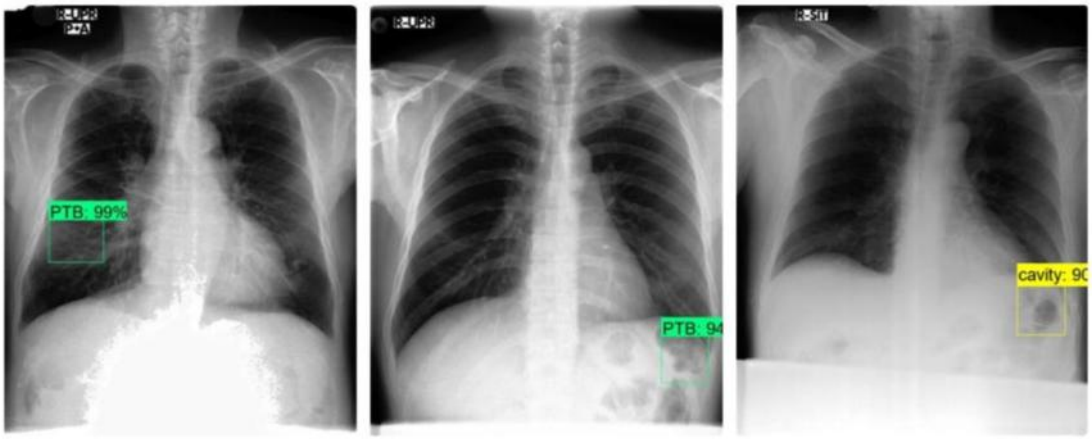

Tables

Table 1. Composition of final testing dataset.

Classification	Number of radiographs
Negative chest radiographs	**36**
Radiographs with PTB opacities and/or cavity	**32**
Radiographs with PTB opacities without cavity	4
Radiographs with PTB opacities and cavity	28
Pathologic Radiographs without PTB and cavity	**32**
Pneumonia	21
Pleural effusion	5
Pulmonary congestion	2
Bronchitis/bronchiectasis	1
Pulmonary nodule	1
Fibrosis	1
Subsegmental atelectasis	1
GRAND TOTAL	**100**

Table 2. 2 x 2 Contingency table for analysis as a screening tool.

		Radiographs verified by panel of radiologists		
		Positive	**Negative**	**TOTAL**
Radiographs identified by the detector	**Positive**	35	8	43
	Negative	3	54	57
	TOTAL	38	62	100

Table 3. Summary table for analysis as a screening tool.

Parameter	Value	Lower-Upper 95% Confidence Intervals
Sensitivity	92.11%	79.2, 97.28%
Specificity	87.10%	76.55, 93.31%
Accuracy	89.00%	81.37, 93.75%

Table 4. 2 x 2 Contingency table for analysis as a locator of PTB opacities and cavity

		Lung regions verified by panel of radiologists		
		Positive	**Negative**	**TOTAL**
Lung regions identified by the detector	**Positive**	79	10	89
	Negative	15	501	516
	TOTAL	94	511	605

Table 5. Summary table for analysis as a locator of PTB opacities and cavity

Parameter	Value	Lower-Upper 95% Confidence Intervals
Sensitivity	84.04%	75.33, 90.08%
Specificity	98.04%	96.44, 98.93%
Accuracy	95.87%	93.97, 97.19%

Table 6. Summary table of studies on computer-aided detection of PTB, as a screening tool.

Author, Year	Algorithm used	Training samples	Sensitivity	Specificity	Accuracy
This study, as a screening tool	Faster R-CNN+	554	92.11%	87.1%	89.00 %
Rohmah et al. 2013.[13]	Histogram analysis	50	93.3 %	97.5 %	95.70 %
Tan et al. 2012.[14]	Histogram analysis	64	91%	95.4%	92.9%
Hwang et al. 2016.[4]	CNN‡	7500			90.3%
Lakhani et al. 2017.[5]	CNN‡	1016	97.3%	100%	
Pande et al. 2016.[2]	Proprietary	Undisclosed	1: 86%	1: 41%	
Includes the following studies:			2: 100%	2: 23%	
1: Maduskar, et al.[15]			3: 95%	3: 33%	
			4: 91%	4: 52%	
2: Muyoyeta et al.[15]			5: 85%	5: 69%	
			6: 77%	6: 79%	
3-8: Breuninger, et al.[16]			7: 62%	7: 85%	
			8: 47%	8: 94%	

+ R-CNN = Region Convolutional Neural Network, ‡CNN = Convolutional Neural Network

Table 7. Summary table of studies on computer-aided detection of PTB, as a locator.

Author, Year	Algorithm used	Training samples	Sensitivity	Specificity	Accuracy
This study, as a locator	Faster R-CNN+	554	84.04%	98.04%	95.87 %
Xu et al. 2013.[17]	GTM, LBP, HOG‡	30	69.4 - 78.8%	81.6 - 86.8%	75.5 - 82.8%

+ R-CNN = Region Convolutional Neural Network
‡GTM = Gaussian-model-based template matching, LBP = local binary patterns, HOG = histogram of oriented gradients

Parental Perception and Attitude on Childhood Immunization and Other Government Healthcare Programs after the Dengue Vaccine Controversy: A Hospital-Based-Cross-Sectional Study*

Elaine Diane Santos-Sanchez, MD[1]

The dengue vaccine controversy in the Philippines caused significant public anxiety affecting childhood vaccines, as well as other healthcare programs. An assessment of parental perception and attitude on childhood immunization and other government healthcare programs after the dengue vaccine controversy is lacking in the local setting. This study determined the perception and attitude of parents on childhood immunization and other government health care programs after the dengue vaccine controversy at a tertiary pediatric hospital in Quezon City.

A hospital-based cross-sectional survey was done at a tertiary pediatric hospital. A total of 96 subjects participated in the study. Parents with children ages 9 to 18 years old whose child was either vaccinated or non-vaccinated with dengue vaccine seen in the dengue clinic, outpatient department and private clinics were invited to answer the structured questionnaire. Proportional stratified sampling was employed. Mann Whitney U-test compared the perception and attitude scores between parents of children who were recipients and non-recipients of dengue vaccine. A p-value of <0.05 was considered as significant.

The overall perception and attitude of parents on childhood immunization, deworming and vitamin A supplementation did not differ significantly between parents of non-dengue vaccinated children and dengue-vaccinated children (P-value >0.05). Sociodemographic factors such as gender, marital status, educational attainment, employment and economic status did not differ significantly in their perception and attitude in terms of childhood immunization, deworming and vitamin A supplementation. (P-value >0.05)

The overall perception and attitude of parents in both groups showed no significant difference toward childhood immunization, deworming and vitamin A supplementation. This study showed that there is no association with the overall perception and attitude of parents on childhood immunization, deworming and vitamin A supplementation and their sociodemographic factors.

KEYWORDS: *dengue vaccine, childhood immunization, deworming, vitamin A supplementation*

INTRODUCTION

The World Health Organization (WHO) reported dengue fever as one of the most important mosquito-borne viral illnesses. It is a growing global threat that has rapidly spread to all tropical and subtropical regions in the recent decades, posing significant socioeconomic and disease burden.[1,2] Dengue fever is regarded as one of the major public health problems in the Philippines. In response to this, the Department of Health (DOH) implemented the National Dengue Prevention and Control Program. The strategies of this program include surveillance, case management and

*3rd Place, 2020 Philippine Medical Association Original Research Presentation, September 7, 2020

[1]Resident, Philippine Children's Medical Center, Quezon City

diagnosis, integrated vector management, outbreak response, health promotion, advocacy and research.[3]

Despite the consistent effort of the international and local government to reduce dengue burden, there is still growing global epidemic of dengue hence the WHO Initiative for Vaccine Research (IVR) facilitated the development and introduction of dengue vaccines.[4] CYD-TDV (live attenuated dengue vaccine) was developed by Sanofi Pasteur (Lyon, France) for use in individuals aged 9 to 45 years, in five low or middle income countries: Brazil, Costa Rica, El Salvador, Mexico and Philippines.[5] The DOH launched its school-based dengue immunization program last April 4, 2016 vaccinating grade 4 students from the National Capital Region, CALABARZON, and Central Luzon.[6] As of December 2017, approximately 800,000 children were administered with the dengue vaccine.[7]

In November 2017, Sanofi made an official statement that the live attenuated dengue vaccine may pose severe dengue among those who had not contracted the disease previously.[8] This announcement led to the temporary suspension of school-based dengue vaccination program which then ensued panic and confusion among parents and relatives of children vaccinated with dengue vaccine. The controversy has gained much attention affecting government-initiated health programs. The fear from this controversy resulted to parents refusing to vaccinate their children even against established vaccine preventable diseases, which gave rise to a phenomenon known as vaccine hesitancy. The phrase "vaccine hesitancy" refers to a delay in acceptance or refusal of safe vaccines despite the availability of vaccination services. To date, 1 in 5 children worldwide fail to receive routine immunization, and about 1.5 million children die each year of diseases that could be prevented by vaccination. Concern over vaccine safety is one of the most dominant reasons for vaccine hesitancy. These concerns could have been brought by widely circulating media reports highlighting a rare occurrence of an adverse reaction to a vaccine or associating certain disorders to vaccines or their components. Most of these concerns were unfounded or without clear evidence and yet somehow managed to instill fear in the minds of parents.[9] The series of events led the author to come up with a study which aims to determine parents' perception and attitude towards childhood immunization and other government healthcare programs after the dengue vaccine controversy.

METHODOLOGY

Study Design

This is a cross sectional study conducted in the Outpatient Department of a Tertiary Pediatric Hospital in Quezon City.

Study Participants

Inclusion Criteria

The participants enrolled in this study are parents of children ages 9 to 18 years old consulting at the Outpatient Department of a Tertiary Pediatric Hospital regardless of vaccination status for dengue fever. They were invited to participate in the survey and were requested to sign a written informed consent before the questionnaire administration.

Sample size

The population of this study are parents of children ages 9 to 18 years old whose child was either vaccinated or non-vaccinated with the dengue vaccine seen in the dengue clinic, outpatient department and private clinics. In the hospital census, there were around 11,259 members of this population (7,866 from the dengue clinic, 2,618 from OPD charity clinic and 775 from the private clinics).

The formula used to compute the sample size necessary to answer the primary objective of this descriptive study is

$$n = deff \times \frac{N\hat{p}\hat{q}}{\frac{d^2}{1.96^2}(N-1) + \hat{p}\hat{q}}$$

where

n = sample size
$deff$ = design effect
N = population size
$\hat{p}$ = the estimated proportion
$\hat{q} = 1 - \hat{p}$
d = desired absolute precision or absolute level of precision

Using a design effect of 1, population size of 11,259, 50% hypothesized frequency to give the highest possible minimum sample size, 95% precision, and 95% confidence interval; the computed minimum sample size is 96. Using proportional stratified sampling, 67 were parents of children from the dengue clinic while 22 were parents from the OPD charity clinic and 7 were parents from the private clinics.

Study procedure

The study protocol was reviewed and approved by PCMC Institutional Research Ethics Committee (IREC) prior to the conduct of the study.

The principal investigator conducted a research orientation with the members of the research team. Duties and responsibilities were assigned to each member before commencement of the study.

The principal investigator conducted a focused group discussion involving eight parents. There was equal number of male and female participants with age 20 years old and above, with children consulting at the outpatient department. The length of the focus group discussion (FGD) was 60 minutes. The FGD was held at a consultation room near the outpatient clinic. The participants answered ten open-ended questions (Appendix I) after they have voluntarily signed a written informed consent (Appendix II). The principal investigator formulated a 13-item questionnaire from the data gathered from the focused group discussion conducted.

Study instrument

The questionnaire used in this study was formulated from the data gathered from the focused group discussion. This questionnaire was validated using both the English and Filipino languages. The internal consistency of the questionnaire was measured using Cronbach's alpha while Interclass correlation coefficient was used to measure test-retest reliability.

The minimum sample size requirement to validate the tool was 26 based on the target Cronbach's alpha of 0.90 for a 13-item questionnaire with significance level of 5%, power of 95%, and target of excluding Cronbach's alpha of 0.7 in the confidence interval.

The items were answered by each participant using a five-point Likert scale. The possible responses ranged from “strongly disagree” to “strongly agree”. A score of zero to four could be received for each statement.

The internal consistency of the questionnaire showed a high Cronbach alpha of .756 which indicates good internal consistency among the items in the questionnaire. This means that the items consistently measure the parental perceptions and attitudes on childhood immunization and other government healthcare programs after the dengue vaccine controversy.

The test-retest reliability of the questionnaire which was measured by Interclass correlation showed a high test-retest correlation of 0.877 which indicates good reliability of the questionnaire. This means that individuals consistently report the same responses during different time periods. (See Appendix III)

New participants for the study were then recruited and oriented by the principal investigator. The investigator explained the study thoroughly and gave the participants adequate time and opportunity to raise questions. All inquiries from the participants were addressed. The participants were asked to sign a voluntary informed consent (See Appendix IV) after the investigator made sure that all of the subjects have fully understood the proceedings. Once qualified, the data from each participant were gathered using the General Information Sheet. Each subject answered a 13-item questionnaire formulated from the previously conducted focused group discussion. (See Appendix V) The data were encoded and analyzed. (See Appendix VI)

Ethical considerations

This research was reviewed and approved by the Institutional Review and Ethics Committee. The principal investigator proceeded with the study after its approval. All the qualified participants signed voluntarily the informed consent before proceeding with the study. Each participant was oriented and was given the right to withdraw at any point of the study. There was no compensation in any form given to any of the participants.

The investigators ensured the confidentiality of the data gathered in this study. The participants were assured that all the results were used solely for the purpose of this study.

Data processing and Data analysis

The sociodemographic characteristics of the participant were described as categorical variables and summarized using frequencies and proportion. The perceptions and attitudes of parents, the distribution of parents who strongly agree, agree, neutral, disagree, and strongly disagree per question in the tool were summarized using frequencies and proportion. A numerical value was assigned to each response (0- strongly disagree, 1-disagree, 2- neutral, 3-agree, 4-strongly agree). The median and range of ratings per item in the questionnaire were also described. Mann Whitney U-test was used to compare the perception and attitude scores between parents of children who were recipients and non-recipients of dengue vaccine. SPSS 23 was used in all analysis. A p-value of <0.05 was considered as significant.

The answers to the 13-item questionnaire were grouped according to the following variables: 1. Parental perception towards childhood immunization, 2. Parental attitude towards childhood immunization, 3. Parental perception towards deworming and 4. Parental perception towards vitamin A supplementation then the weighted means were computed using the five-point scale with the following interpretation:

Range	Verbal Interpretation
0.00 to 0.79	Generally, strongly disagree
0.80 to 1.59	Generally, disagree
1.60 to 2.39	Generally, not sure
2.40 to 3.19	Generally, agree
3.20 to 4.00	Generally, strongly agree

RESULTS

A. Demographic Data

A total of 96 participants completed the questionnaire. Majority (51%) of the respondents were 30 to 41 years old with a mean age of 39. Eighty-six percent (86%) of the respondents were females. More than half (67%) were married and 64% of the respondents were high school graduates. Majority (92%) of the participants belong to the lower income class. Thirty one percent (31%) of the participants have children who received the Dengue vaccine (see Table 1).

Table 1. Comparative Frequency and Percentage Distribution of the Sociodemographic Characteristics of Parents of Dengue Vaccine Recipients and Non-Dengue Vaccine Recipients

Characteristics (n=96)	Dengue Vaccine Non-Recipients n=66, n (%)	Dengue Vaccine Recipients n=30, n (%)
Age of Parents		
18-29	9 (13.6)	1 (3.3)
30-41	35 (53.0)	14 (46.7)
42-53	19 (28.8)	14 (46.7)
54 and above	3 (4.5)	1 (3.3)
Gender		
Male	7 (10.6)	3 (10.0)
Female	57 (89.4)	27 (90.0)
Marital Status		
Single	20 (30.3)	6 (20.0)
Married	41 (62.1)	23 (76.7)
Separated	4 (6.1)	1 (3.3)
Widowed	1 (1.5)	0 (0.0)
Educational Attainment of Parents		
Primary	5 (7.6)	1 (3.3)
Secondary	40 (60.6)	21 (70.0)
College	13 (19.7)	4 (13.3)
Graduate Level	7 (10.6)	4 (13.3)
Vocational	1 (1.5)	0 (0.0)
Employment		
Employed	21 (31.8)	8 (26.6)
Unemployed	45 (68.2)	22 (73.3)
Monthly income		
Upper Class (>/=80,000)	2 (3.0)	1 (3.3)
Middle Class (30, 000-79, 999)	3 (4.5)	2 (6.7)
Lower Class (</=29,000 pesos)	61 (92.4)	27 (90.0)
Number of Children		
1	8 (12.1)	4 (13.3)
2	14 (21.2)	9 (30.0)
3	23 (34.8)	10 (33.3)
>/=4	21 (31.8)	7 (23.3)
Number of Children given Dengue Vaccine		
1	0 (0.0)	22 (73.3)
2	0 (0.0)	8 (26.6)
3	0 (0.0)	0 (0.0)
>/=4	0 (0.0)	0 (0.0)

B. Parental Perception on Childhood Immunization

Eighty five percent (85%) of parents of dengue vaccine non-recipients and 83% of dengue vaccine recipients responded positively that vaccines strengthen their child's immunity (agree and strongly agree). The two groups perceived childhood immunization as safe and effective (dengue vaccine non-recipients 86.9%, dengue vaccine recipients 73.3%). Majority of the respondents (56.2%) are not sure if newer vaccines carry more risks and adverse effects. Parents from both groups perceived that doctors are still the most reliable source of information about childhood mmunization (dengue vaccine non-recipients 90.8% dengue vaccine recipients 96.6%). Thirty-three percent of dengue vaccine non-recipients and 43.4% of dengue vaccine recipients are not sure if childhood vaccines cause harmful adverse effects, illness and even death. Fifty-five percent (55%) of the respondents agreed and strongly agreed that information about benefits and side effects of childhood vaccines are readily available and accessible. (See Table 2)

The overall perception of parents towards childhood immunization after the dengue vaccine controversy averaged to 2.56 ± 0.51 with a verbal interpretation of generally agree. The mean score on perception of non-dengue vaccinated children (2.56 ± 0.49) and dengue vaccinated children (2.54 ± 0.56) are not significantly different (P-value 0.629).

Table 2. Perception of Parents on Childhood Immunization after the Dengue Vaccine Controversy

Variables	Likert scale responses	(n=96), n (%)	Dengue vaccine Non-Recipients (n=66), n (%)	Dengue vaccine Recipients (n=30), n (%)	P-value
Childhood vaccines strengthen my child's immunity	Strongly disagree	3 (3.1)	1 (1.5)	2 (6.6)	0.1056
	Disagree	1 (1.0)	1 (1.5)	0 (0.0)	
	Not sure	11 (11.4)	8 (12.1)	3 (10)	
	Agree	36 (37.5)	21 (31.8)	15 (50)	
	Strongly Agree	45 (46.8)	35 (53)	10 (33.3)	
Childhood immunization is safe and effective	Strongly disagree	4 (4.1)	2 (3.0)	2 (6.6)	0.1959
	Disagree	2 (2.0)	1 (1.5)	1 (3.3)	
	Not sure	10 (10.0)	5 (7.5)	5 (16.6)	
	Agree	43 (44.7)	31 (46.9)	12 (40.0)	
	Strongly Agree	37 (38.5)	27 (40.0)	10 (33.3)	
Newer vaccines carry more risks and adverse effects.	Strongly disagree	15 (15.6)	12 (7.9)	3 (10.0)	0.1813
	Disagree	15 (15.6)	10 (15)	5 (16.6)	
	Not sure	54 (56.2)	37 (56)	17 (56.6)	
	Agree	7 (7.2)	5 (7.5)	2 (6.6)	
	Strongly Agree	5 (5.2)	2 (3.0)	3 (10.0)	
Doctors are the most reliable sources of information about childhood immunization.	Strongly disagree	2 (2.0)	2 (3.0)	0 (0.0)	0.9891
	Disagree	1 (1.0)	1 (1.5)	0 (0.0)	
	Not sure	4 (4.1)	3 (4.5)	1 (3.3)	
	Agree	32 (33.3)	18 (27.2)	14 (46.6)	
	Strongly Agree	57 (59.3)	42 (63.6)	15 (50)	
Childhood vaccines cause many harmful adverse effects, illness and even death.	Strongly disagree	22 (22.9)	17 (25.7)	5 (3.3)	0.0996
	Disagree	35 (36.4)	26 (39.3)	9 (30.0)	
	Not sure	35 (36.4)	22 (33.3)	13 (43.4)	
	Agree	2 (2.0)	1 (1.5)	1 (3.3)	
	Strongly Agree	2 (2.0)	0 (0.0)	2 (6.6)	
Information about benefits and side effects of childhood vaccines are readily available.	Strongly disagree	3 (3.10)	2 (3.0)	1 (3.3)	0.1214
	Disagree	7 (7.2)	5 (7.5)	2 (6.6)	
	Not sure	33 (34.3)	20 (30)	13 (43.4)	
	Agree	41 (42.7)	30 (45.4)	11 (36.6)	
	Strongly Agree	12 (12.5)	2 (3.0)	3 (10.0)	
Overall perception	Mean	2.56	2.56	2.54	0.629
	SD	0.51	0.49	0.56	

C. Parental Attitude on Childhood Immunization

Parents in both groups (dengue vaccine non-recipients 87.8%, dengue vaccine recipients 79.0%) agreed to vaccinate their children by a doctor or in the presence of a doctor. The two groups affirmed (87.4%) that a general consult must be done before vaccine administration. Majority, 72.8% of these parents (dengue vaccine non-recipients 77.2%, dengue vaccine recipients 63.2%) showed positive attitude towards childhood immunization provided that they were informed and understood the expected side effects before vaccine administration. (See Table 3)

The overall attitude of parents towards childhood immunization after the dengue vaccine controversy averaged to 3.04 ± 0.77 with a verbal interpretation of generally agree. The mean score on attitude of parents of non-dengue vaccinated children (3.07 ± 0.73) and dengue vaccinated children (2.80 ± 1.08) towards childhood immunization after the dengue vaccine controversy did not differ significantly (P-value 0.778).

Table 3. Attitude of Parents on Childhood Immunization after the Dengue Vaccine Controversy

Variables		(n=96), n (%)	Dengue vaccine Non-Recipients (n=66), n (%)	Dengue vaccine Recipients (n=30), n (%)	P-value
I will only allow my children to be vaccinated during their scheduled immunization if:					
It will be administered by a doctor or in a presence of a doctor.	Strongly disagree	3 (3.1)	2 (3.0)	1 (3.3)	
	Disagree	1 (1.0)	0 (0.0)	1 (3.3)	
	Not sure	10 (10.4)	6 (9.0)	4 (13.3)	
	Agree	50 (52.0)	36 (54.5)	14 (46.6)	0.9861
	Strongly Agree	32 (33.3)	22 (33.3)	10 (33.3)	
Check-up will be done before giving the vaccines.	Strongly disagree	3 (3.1)	2 (3.0)	1 (3.3)	
	Disagree	2 (2.0)	2 (3.0)	0 (0.0)	
	Not sure	7 (7.2)	5 (1.5)	2 (3.3)	0.8112
	Agree	47 (48.9)	31 (46.9)	16 (53.5)	
	Strongly Agree	37 (38.5)	26 (39.3)	11 (36.6)	
I have fully understood the expected side effects.	Strongly disagree	3 (3.1)	2 (3.0)	1 (3.3)	
	Disagree	2 (2.0)	1 (1.5)	1 (3.3)	
	Not sure	21 (21.8)	12 (18.1)	9 (30)	0.6389
	Agree	47 (48.9)	36 (54.5)	11 (36.6)	
	Strongly Agree	23 (23.9)	15 (22.7)	8 (26.6)	
Overall Attitude	Mean	3.04	3.07	2.80	0.778
	SD	0.77	0.73	1.08	

D. Parental Perception on Government Healthcare Programs

This study determined the effect of dengue vaccine controversy on other government healthcare programs. The results showed that 73% of parents of dengue vaccine non-recipients and 70% of parents of dengue vaccine recipients perceived that deworming is safe and effective. The participants from both groups agreed (39.5%) and strongly agreed (32.3%) that parasitism can lead to malnutrition. However, 35.4% of parents from both groups (dengue vaccine non-recipients 33.3%, dengue vaccine recipients 40%) are uncertain of the adverse effects of deworming. (see Table 4)

The overall mean perception scores of parents towards deworming is 2.65 ± 0.62 with verbal interpretation of generally agree. The mean score on perception of non-dengue vaccinated children (2.65±0.65) and dengue vaccinated children (2.63 ± 0.33) on deworming are not significantly different (P-value 0.076).

Ninety percent of the respondents perceived that vitamin A supplementation is safe and effective. It has a mean score of 3.24 with a verbal interpretation of generally agree. The mean score on perception of non-dengue vaccinated children (3.28±0.82) and dengue vaccinated children (2.90±1.60) on vitamin A supplementation are not significantly different (P-value 0.938).

Table 4. Perception of Parents on Other Government Health Care Programs

Variables		(n=96), n (%)	Dengue vaccine Non-Recipients (n=66), n (%)	Dengue vaccine Recipients (n=30), n (%)	P-value
Government healthcare programs such as deworming is safe and effective.	Strongly disagree	2 (2.0)	1 (1.5)	1 (3.3)	0.969
	Disagree	1 (1.0)	1 (1.5)	0 (0.0)	
	Not sure	24 (25.0)	16 (24.2)	8 (26.6)	
	Agree	38 (39.5)	27 (40.9)	11 (36.6)	
	Strongly Agree	31 (32.3)	21 (31.8)	10 (33.3)	
Parasitic worms in children can lead to malnutrition.	Strongly disagree	2 (2.0)	1 (1.5)	1 (3.3)	0.3827
	Disagree	1 (1.0)	0 (0.0)	1 (3.3)	
	Not sure	6 (6.2)	3 (4.5)	3 (10)	
	Agree	44 (45.8)	31 (46.9)	13 (43.3)	
	Strongly Agree	43 (44.7)	31 (46.9)	12 (40)	
Deworming has harmful adverse effects to children and some even lead to deaths.	Strongly disagree	14 (14.5)	9 (13.6)	5 (3.3)	0.2224
	Disagree	26 (27)	17 (25.7)	9 (30)	
	Not sure	34 (35.4)	22 (33.3)	12 (40)	
	Agree	12 (12.5)	10 (15.1)	2 (6.6)	
	Strongly Agree	10 (10.4)	8 (12.1)	2 (6.6)	
Overall Perception	Mean	2.65	2.65	2.63	0.076
	SD	0.62	0.65	0.33	
Government healthcare programs such as Vitamin A Supplementation is safe and effective.	Strongly disagree	2 (2.0)	1 (1.5)	1 (3.3)	0.9380
	Disagree	1 (1.0)	1 (1.5)	0 (0.0)	
	Not sure	7 (7.2)	2 (3.0)	5 (16.6)	
	Agree	41 (42.7)	32 (48.4)	9 (30)	
	Strongly Agree	45 (46.8)	30 (45.4)	15 (50)	
Overall Perception	Mean	3.24	3.28	2.90	0.938
	SD	0.93	0.82	1.60	

E. Association of Sociodemographic Characteristics and Parental Perception and Attitude on Childhood Immunization, Deworming and Vitamin A supplementation

The overall mean perception on childhood immunization of female and male parents is 2.56. It has a verbal interpretation of generally agree. Analysis showed that there is no significant difference on the perception of female and male respondents on childhood immunization (P-value 0.400).

The overall mean attitude on childhood immunization of female and male parents is 3.04 with a verbal interpretation of generally agree. Analysis showed that there is no significant difference on the attitude of female and male respondents on childhood immunization (P-value 0.523).

The evaluation of the overall mean perception of female and male parents on deworming is 2.65. It has a verbal interpretation of generally agree. Analysis showed that there is no significant difference on the perception of female and male respondents on deworming (P-value 0.980).

Assessment of the overall mean perception of female and male parents on vitamin A supplementation is 3.24 with a verbal interpretation of generally strongly agree. This study showed that there is no significant difference on the gender of parents and their perception on vitamin A supplementation (P-value 0.901). (See Table 5)

Table 5. Association of Gender and Parental Perception and Attitude on Childhood Immunization, Deworming and Vitamin A supplementation

Variables		Overall Mean	Female n = 84 (87.5%)	Male n = 12 (12.5%)	P-value
Perception on immunization	Mean	2.56	2.57	2.47	0.400
	SD	0.51	0.49	0.66	
Attitude on immunization	Mean	3.04	3.07	2.80	0.523
	SD	0.77	0.73	1.08	
Perception on deworming	Mean	2.65	2.65	2.63	0.980
	SD	0.62	0.65	0.33	
Perception on Vitamin A supplementation	Mean	3.24	3.28	2.90	0.901
	SD	0.93	0.82	1.60	

The result of this study showed that the overall mean perception on childhood immunization of single and married parents is 2.56. It has a verbal interpretation of generally agree. The data in this study showed that there is no significant difference on the marital status of parents and their perception on childhood immunization (P-value 0.533).

The outcome of this study demonstrates that the overall mean attitude on childhood immunization of single and married parents is 3.04. It is interpreted as generally agree. The result of the evaluation showed that there is no significant difference on the perception of single and married parents on childhood immunization (P-value 0.682).

The overall mean perception on deworming of single and married parents is 2.65. The mean is verbally interpreted as generally agree. Analysis showed that there is no significant difference on the marital status of parents and their perception on deworming (P-value 0.643).

The analysis of this study revealed that the overall mean perception of single and married parents on vitamin A supplementation is 3.24. This study showed that regardless of marital status, the respondents generally strongly agreed on vitamin A supplementation. Analysis showed that there is no significant difference on the marital status of parents and their perception on vitamin A supplementation (P-value 0.997). (See Table 6)

Table 6. Association of Marital Status and Parental Perception and Attitude on Childhood Immunization, Deworming and Vitamin A supplementation

Variables		Overall Mean	Single, Widowed, or Separated n = 30 (87.5%)	Married n = 66 (12.5%)	P-value
Perception on immunization	Mean	2.56	2.52	2.57	0.533
	SD	0.51	0.51	0.51	
Attitude on immunization	Mean	3.04	3.00	3.06	0.682
	SD	0.77	0.98	0.64	
Perception on deworming	Mean	2.65	2.67	2.64	0.643
	SD	0.62	0.67	0.60	
Perception on Vitamin A supplementation	Mean	3.24	3.09	3.31	0.997
	SD	0.93	1.25	0.71	

The overall mean perception on childhood immunization of parents with primary, secondary or vocational and college or graduate level of education is 2.56. It has a verbal interpretation of generally agree. The analysis of this study showed that there is no significant difference on the educational attainment of parents and their perception on childhood immunization (P-value 0.090).

The results of this study demonstrate that the overall mean attitude on childhood immunization of parents with primary, secondary or vocational and college or graduate level of education is 3.04. This analysis showed that regardless of educational attainment, the respondents generally agree on childhood immunization. The evaluation of this report showed that there is no significant difference on the level of

education of parents and their attitude on childhood immunization (P-value 0.304).

The analysis of this study showed that the overall mean perception on deworming of parents with primary, secondary or vocational and college or graduate level of education is 2.65. This study shows that parents generally agree on deworming regardless of educational attainment. Further analysis showed that there is no significant difference on the educational attainment of parents and their perception on deworming (P-value 0.787).

The overall mean perception of parents of all level of education on vitamin A supplementation is 3.24. This data showed that regardless of parental level of education, the respondents generally strongly agreed on vitamin A supplementation. There is no significant difference on parents' educational attainment and their perception on vitamin A supplementation (P-value 0.827). (See Table 7)

Table 7. Association of Educational Attainment and Parental Perception and Attitude on Childhood Immunization, Deworming and Vitamin A Supplementation

Variables		Overall Mean	Primary, Secondary or Vocational n = 30 (%)	College or Graduate n = 66 (12.5%)	P-value
Perception on immunization	Mean	2.56	2.50	2.69	0.090
	SD	0.51	0.50	0.51	
Attitude on immunization	Mean	3.04	2.98	3.17	0.304
	SD	0.77	0.81	0.67	
Perception on deworming	Mean	2.65	2.66	2.63	0.787
	SD	0.62	0.69	0.42	
Perception on Vitamin A supplementation	Mean	3.24	3.24	3.24	0.827
	SD	0.93	0.91	0.99	

The overall mean perception (2.56) and attitude (3.04) regardless of employment status on childhood immunization showed that the parents generally agreed on childhood immunization. Statistics showed that there is no significant difference on the employment status of parents and their perception and attitude on childhood immunization. (See Table 8)

The overall mean perception of parents on deworming regardless of employment status is 2.65. The employed and unemployed parents generally agreed on deworming. There is no significant difference regardless of employment status of parents and their perception on deworming (P-value 0.964).

This study showed that the overall mean perception on vitamin A supplementation of both unemployed and employed parents is 3.24. The parents generally strongly agreed on vitamin A supplementation regardless of employment status. Analysis showed that there is no significant difference on the perception of unemployed and employed parents on vitamin A supplementation (P-value 0.865).

Table 8. Association of Employment Status and Parental Perception and Attitude on Childhood Immunization, Deworming and Vitamin A supplementation

Variables		Overall	Unemployed n = 67 (69.8%)	Employed n = 29 (30.2%)	P-value
Perception on immunization	Mean	2.56	2.62	2.42	0.326
	SD	0.51	0.44	0.61	
Attitude on immunization	Mean	3.04	3.05	3.01	0.564
	SD	0.77	0.65	1.00	
Perception on deworming	Mean	2.65	2.67	2.61	0.964
	SD	0.62	0.59	0.68	
Perception on Vitamin A supplementation	Mean	3.24	3.25	3.21	0.865
	SD	0.93	0.88	1.05	

The result of the study showed that the overall mean perception on childhood immunization and economic status is 2.56. The parents of different economic status generally agreed to have their child vaccinated. Analysis showed that there is no significant difference on the economic status of parents and their perception on childhood immunization (P-value 0.947).

The overall mean attitude on childhood immunization of lower class and middle- or upper-class parents is 3.04 with a verbal interpretation of generally agree. Analysis showed that there is no significant difference on the attitude of lower class and middle- or upper-class parents on childhood immunization (P-value 0.631).

This study demonstrates that the overall mean perception of parents of different economic status on deworming is 2.65. Parents with different economic status generally agreed on deworming. The parents' perception on deworming has no significant difference regardless of economic status (P-value 0.703).

The overall mean perception of lower class and middle- or upper-class parents on vitamin A supplementation is 3.24. These parents generally strongly agreed on vitamin A supplementation regardless of their economic status. Analysis showed that there is no significant difference on the perception of lower class and middle- or upper-class parents on vitamin A supplementation (P-value 0.425). (See Table 9)

Table 9. Association of Economic Status and Parental Perception and Attitude on Childhood Immunization, Deworming and Vitamin A supplementation

Variables		Overall	Lower class n = 88 (91.7%)	Middle or Upper class n = 8 (8.3%)	P-value
Perception on immunization	Mean	2.56	2.56	2.52	0.947
	SD	0.51	0.50	0.61	
Attitude on immunization	Mean	3.04	3.04	3.00	0.631
	SD	0.77	0.76	0.91	
Perception on deworming	Mean	2.65	2.65	2.62	0.703
	SD	0.62	0.62	0.60	
Perception on Vitamin A supplementation	Mean	3.24	3.23	3.37	0.425
	SD	0.93	0.92	1.06	

DISCUSSION

Vaccine safety scares are circumstances in which unwanted events are rightly or wrongly connected with vaccination and create feelings of anxiety and distrust in vaccines and health authorities.[10] These scares have the potential to damage public confidence in vaccines and lower immunization rates, resulting in disease outbreaks and deaths.[11]

In the Philippines, dengue vaccination was suspended in December 2017 when the vaccine manufacturer issued a warning against its own vaccine. Most vaccine memoranda reported on social media and on televisions were on vaccine related deaths. This led to significant public anxiety around dengue vaccine and other childhood vaccines, as well as other health interventions such as deworming in both public health programs and private clinics.[12] Parents became more conscious on their children's health and changed their health seeking behavior.[13]

Despite the dengue vaccine controversy, parents in this study (84.3%) perceived that childhood vaccines benefit their children by strengthening their immune system. This is line with the study by Alshammari *et al.* which showed that 60-90% of the respondents were knowledgeable regarding the health benefits of vaccinations in children even though 18.4% of their children had experienced vaccination-related minor adverse effects.[14]

In line with the safety and effectiveness of childhood immunization, 83.2% of parents from

both groups responded positively (agree and strongly agree). However, four percent from both groups believed that childhood vaccines are harmful with majority are from parents with dengue vaccinated children (9.9%). Some of the respondents, 6.1% (dengue vaccine non-recipients 4.5%, dengue vaccine recipients 9.9%), perceived that childhood immunization is unsafe and not effective. This is also evident in the study conducted by Bults *et al*. which showed that fear of side effects or harmful consequences is the most reported reason of parents in declining the H1N1 vaccination in Netherlands.[13]

Kara *et al.*, reported that an increased frequency of vaccine-related adverse events may result in the global perception that vaccines are hazardous, despite continued improvements in vaccine safety.[15] This is also evident in the statement by the SAGE Vaccine Hesitancy Working Group that past negative or positive experience with a particular vaccination can influence hesitancy or willingness to vaccinate. Personal experience or knowledge of someone who experienced an adverse event following immunization (AEFI) can also influence hesitancy.[16] This negative experience by parents with either vaccinated or non-vaccinated children may have led to vaccine hesitancy. This is contrary to a previous study by King *et al.* which showed that the impact of influenza vaccine suspension in Australia is limited to the influenza vaccine alone. It did not affect their confidence in other established vaccination programs.[11]

Twelve percent of parents in this study (dengue vaccine non-recipients 10.5%, dengue vaccine recipients 7.6%) perceived that newer vaccines carry more risks and adverse effects. This is line with the study by Noakes *et al*. which showed that respondents were more comfortable with old vaccines that they felt had been tried and tested. The respondents expressed more anxiety when discussing the introduction of new vaccines.[17] According to SAGE Vaccine Hesitancy Working Group, parents may hesitate to accept a new vaccine when not proven to be effective.[16]

Despite the vaccine safety scare, majority of parents (92.6%) in this study agreed or strongly agreed that doctors are the most reliable source of information about childhood immunization. However, 10.3% of parents from both groups disagreed or strongly disagreed that this information is readily available or accessible. This is evident in the local study conducted by Valido *et al*. which showed that trust in public health institutions has been criticized during the dengue vaccine controversy. Doctors are the most cited trustworthy sources of information. The lack of avenues and confidence in discussing what transpired in the implementation of the vaccination program has led to loss of trust in the dengue vaccination as well as other immunization public health programs.[18]

King *et al.* concluded that parents accorded great importance on information from a trustworthy and reputable source. General practitioners were acknowledged as a trusted source of information. However, information from physicians was not always a practical solution as they are not immediately accessible.[11]

This perception of inaccessibility of reliable information led parents to seek additional medical information from social media, television or internet. Knowledge has been identified as an important factor which influence parents' decisions. A wider source of information has been related to a better level of knowledge in the frame of decision-making about vaccination.[19] The absence of clear messages from trusted heath authorities created an information void for parents, inadvertently allowing the perpetuation and persistence of a negative association.[11]

Parents became more hypervigilant about their child's health after the dengue vaccine controversy. Majority of parents in this study are still willing to give the scheduled childhood vaccines to their children provided that it is administered by a doctor or at least in the presence of a primary physician during administration (85.3%), after a thorough general consult has been done (87.4%) and after they have fully understood the benefit and side effects of the vaccine (72.8%). This is evident in the local study by Valido *et al.* wherein there is a

greater demand for more and specific information during the dengue vaccine controversy in the Philippines. After the dengue vaccine scare, these parents now preferred to consult from private health practitioners.[18]

A qualitative study conducted in the United Kingdom (UK) to examine parents' views of the Measles Mumps Rubella (MMR) vaccine controversy determined that health scares increase parental information needs, particularly in relation to future vaccination intent. However, it appears that for many study parents, in the circumstance of the suspension, vaccination was conditional on the provision of a clear safety message via authoritative sources.[11]

Despite the vaccine safety scare, majority of the parents in this study still believed that other government healthcare programs such as deworming and vitamin A supplementation are safe, effective and beneficial. However, 22.9% of the respondents perceived deworming as harmful. This is in line with the study by Larson et al. which showed that dengue vaccine panic does not only undermined trust in the dengue vaccine, vaccines more broadly, but also other interventions provided by health clinics, such as deworming medication.[12]

The overall perception and attitude of parents towards childhood immunization in this study did not differ significantly in terms of gender, marital status, educational attainment, employment status and economic status. This is in line with the study by Braczkowska *et al*. which showed that economic status of families had no significant effect on the opinions about safety of vaccination.[20] However this is in contrast with the findings of an earlier study by Braczkowska *et al*. which showed that parents with a higher level of education and past vaccine-related experience encountered more frequent negative opinions on vaccination.[21] A study by Brown et al. showed that lower vaccine uptake was associated to lower parental income and lower parental education which is in contrast with our study.[22]

CONCLUSION and RECOMMENDATIONS

We interviewed a total of 96 parents with children 9 to 18 years old who were non-dengue vaccine recipients and dengue vaccine recipients using a self-administered questionnaire.

The overall perception and attitude of parents in this study showed that they generally agree on childhood immunization, deworming and vitamin A supplementation despite the dengue vaccine controversy. There was no significant difference in the overall perception and attitude of parents whose children were or were not recipients of the dengue vaccine in terms of childhood immunization, deworming and vitamin A supplementation after the dengue vaccine controversy. This study showed that there is no association on the overall perception and attitude of parents on childhood immunization, deworming and vitamin A supplementation and their gender, marital status, educational attainment, employment and economic status.

Future similar studies may be conducted in other provinces or regions to determine parental perception and attitude toward the government's immunization program and other health care programs.

REFERENCES

1. World Health Organization. Dengue and severe dengue. 2018

2. Wilder-Smith A, Murray A, Quam M. Epidemiology of dengue: past, present and future prospects. Clinical Epidemiology. 2013; 299.

3. Department of Health. Dengue Prevention and Control Program (n/d)

4. World Health Organization. Dengue vaccine research. 2017

5. Gatell H, Alpuche-Aranda C, Santos-Preciado M, Avila M. Dengue vaccine: local decisions, global consequences. Bulletin of the World Health Organization. 2016

6. Bonalos P. DOH starts dengue vaccination program. CNN Philippines. 2016

7. Lardizabal C. DOH: More than 800,000 children vaccinated with Dengvaxia. CNN Philippines. 2017

8. CNN Philippines Staff. Drug firm warns of 'severe disease' from dengue vaccine for people with no prior infection. CNN Philippines. 2017

9. Fatima K, Syed NI. Dengvaxia controversy: impact on vaccine hesitancy. Journal of Global Heath. 2018

10. World Health Organization Regional Office for Europe. Vaccination and Trust: How Concerns arise and the Role of Communication in Mitigating crises. Copenhagen. 2017

11. King C, Leask J. The impact of a vaccine scare on Parental views, Trust and Information Needs: A Qualitative Study in Sydney, Australia. BMC Public Health. 2017

12. Larson HJ, Hatigan-Go K, de Figueiredo A. Vaccine Confidence Plummets in the Philippines Following Dengue Vaccine Scare: Why it Matters to Pandemic Preparedness. Hum Vaccin Immunother. 2019; 15(3):625-627

13. Bults M, Beaujean D, Richardus J, *et al*. Pandemic influenza A (H1N1) vaccination in The Netherlands: Parental reasoning underlying child vaccination choices. Vaccine. 2011; 29 (37):6226-6235

14. Alshammari TM, Subaiea GM, Hussain T, Moin A, Yusuff KB. Parental perceptions, attitudes and acceptance of childhood immunization in Saudi Arabia: A cross sectional study. Vaccine. 2018; 36(1), 23-28.

15. Kara SS, Polat M, Yayla BC, et al. Parental Vaccine Knowledge and Behaviours: a survey of Turkish families. East Mediterr Health J. 2018; 24 (5):451-458

16. SAGE Vaccine Hesitancy Working Group. What influences vaccine acceptance: A model of determinants of vaccine hesitancy. 2013

17. Noakes K, Yarwood J, Salisbury D. Parental Response to the Introduction of a Vaccine Against Human Papilloma Virus. Human Vaccines. 2006; 2(6), 243-248.

18. Valido EM, Laksanawati IS, Utarini A. Acceptability of the Dengue Vaccination Among Parents in Urban Poor Communities of Quezon City, Philippines Before and After Vaccine Suspension. BMC Research Notes. 2018; 11: 661

19. Damnjanović K, Graeber J, Ilić S, *et al*. Parental Decision-Making on Childhood Vaccination. Front Psychol. 2018; 9: 735

20. Braczkowska B, Kowalska M, Barański K, *et al*. Parental Opinions and Attitudes about Children's Vaccination Safety in Silesian Voivodeship, Poland. Int J Environ Res Public Health. 2018; 15(4)

21. Braczkowski B, Kowalska M, Braczkowski R, Barański K. Determinants of vaccine hesitancy. Przegl Epidemiol. 2017;71(2):227-236

22. Brown K, Kroll J, Hudson M, *et al*. Factors underlying parental decisions about combination childhood vaccinations including MMR: A systematic review. *Vaccine*. 2010; *28*(26), 4235–4248. doi: 10.1016/j. vaccine.2010.04.052

Retropharyngeal Sinus Tract Secondary to Glass Shard Impaction in an 8 Month-Old Child; Endoscopic Diagnosis Via Telescope Endoscopy And Management of Sinus Tract by Endoscopic Electrocauterization*

Angelo Miguel P. Parungao, MD[1]
Antonio H. Chua, MD, FPSO-HNS[2]

ABSTRACT

Objectives:

- To present a case of an 8 month-old female who ingested a foreign body that impacted itself into the posterior pharyngeal wall resulting in a retropharyngeal sinus tract
- To discuss the events leading to the diagnosis of the patient
- To explain the reason behind the difficulty of locating the foreign body during rigid esophagoscopy
- To discuss the use of endoscopic cauterization as management of the retropharyngeal sinus tract

Methods:

Design: Case Report
Setting: Tertiary Government Hospital
Patient: One

Results: An 8 month-old female presented with repeated bouts of vomiting with associated refusal to eat. A chest radiograph showed a triangular radiopaque object at the level of T1-T2. Emergency foreign body extraction via rigid esophagoscopy was done, however, no foreign body was seen in the esophagus. An intraoperative chest radiograph showed a foreign body at the previously described location. On repeat esophagoscopy, a linear wound with purulent discharge on the posterior pharyngeal wall was seen. This wound was explored using a 0° telescope revealing a retropharyngeal tract measuring 2.4 cm in length. At the end of the retropharyngeal tract, a glass shard was found and was extracted. This tract was monitored endoscopically 4, 18, 25, and 32 days post-operative, respectively for possible spontaneous closure of the tract. Eventually, after 32 days, noted to persist hence was debrided and was cauterized via electrocautery leading to its closure. Postop monitoring via flexible endoscopy and neck soft tissue lateral x-ray showed complete closure of the retropharyngeal sinus tract.

Conclusion:

An 8 month-old female who ingested a glass shard was presented. The ingestion of pointed or sharp objects may be embedded into the retropharyngeal space and its further advancement may be caused by shearing forces caused by repetitive swallowing and vomiting. Immediate detection of these sharp foreign bodies may prevent formation of such tracts. Therefore, a high index of suspicion must be had in cases where foreign bodies that are not visualized by rigid esophagoscopy by careful inspection of the mucosal wall of the pharyngeal area with further guidance of radiographs. The innovation of endoscopic electrocautery as management of the sinus tract, inspired from the management of fourth branchial cleft sinus tracts, is an effective approach in management.

Keywords: *foreign body impaction, endoscopic cauterization, sharp pointed foreign body*

1st Place, 2020 Philippine Medical Association Case Report Presentation, September 7, 2020
[1]*Resident, Department of Otorhinolaryngology-Head and Neck Surgery, Jose R. Reyes Memorial Medical Center*
[2]*Consultant, Department of Otorhinolaryngology-Head and Neck Surgery, Jose R. Reyes Memorial Medical Center*

CASE REPORT

An 8 month-old female from Tondo, Manila consulted at the emergency room of a government hospital 1 week prior to admission due to vomiting. Though unwitnessed, the patient's parents claimed that the patient had ingested a foreign body. There was no dyspnea, stridor, or hematemesis. Parents claimed x-ray revealed a foreign body in the chest. Due to unavailability of instruments for extraction, the patient was advised to transfer to another institution.

A day later, the patient was brought to another government hospital where a radiograph revealed no foreign body results. The parents were then advised close observation. No medications were given and the patient was then sent home.

Interval history revealed persistence of vomiting and refusal to eat. No further consultation was done, no medications were given.

On the day of the admission, due to persistent bouts of postprandial vomiting, refusal to continue milk feeding and generalized weakness prompted consultation at our emergency room where a chest radiograph showed a triangular radiopaque object at the level of T1 and T2 (Figure 1.). Emergency foreign body extraction via rigid esophagoscopy showed no foreign body. Intraoperative radiograph showed the foreign body in the previously described location (Figure 2.). Repeat esophagoscopy with careful inspection of the pharyngeal wall revealed a linear wound cephalad to the right pyriform sinus. (Figure 3.) Using a 4mm 0° rigid telescope, the wound was explored, revealing a retropharyngeal tract (Figure 4.) This tract measured 2.4cm in length. At the end of the tract, a glass shard was found (Figure 5.). The glass shard measured 1.8 x 1.5 x 0.3 cm(Figure 6.). Intraoperatively, the patient was referred to Thoracic and Cardiovascular Surgery who suggested to do a possible esophagogram and Chest CT Scan with contrast. An endoscopically-guided nasogastric tube insertion was done to ensure that the tube would not be inserted into the above tract. Post-operatively, the patient was placed on NPO and was started on Ampicillin-Sulbactam 349 mg through IV every 6 hours and Paracetamol 68mg through IV every 4 hours as needed for fever. A series of diagnostic esophagoscopies were done (4 times) and neck soft tissue lateral radiographs were done monitoring the retropharyngeal sinus tract of possible spontaneous closure (Figures 7 & 8). However, there was persistence emphysema in the retropharyngeal soft tissue lateral, hence subsequent wound debridement and cauterization were done when spontaneous closure was not observed. Two weeks postoperatively, flexible video endoscopy and repeat neck soft tissue lateral radiograph showed total obliteration of the opening of the retropharyngeal tract (Figure 9). A timeline of the course of the patient's monitoring is illustrated in Figure 10.

DISCUSSION

Presented here is a rare case of a sharp foreign body which embedded itself posterior to the aerodigestive tract creating a retropharyngeal sinus tract. Only a few number of cases of retropharyngeal foreign body have been recorded in recent literature. The most recent case was reported in 2014 by Ziad and colleagues wherein a 21 year old male had complained of severe odynophagia 20 days after eating a chicken meal which resulted in a foreign body being lodged in the posterior wall of the oropharynx. Further workup revealed a sharp metallic foreign body in the retropharyngeal area with abscess formation. Eventually, it was revealed that the foreign body had migrated from the retropharynx to the mediastinum.[1] Mehta and colleagues also described a case wherein a foreign body was seen in a 45 year old male who complained of foreign body sensation in his throat. Radiographic examination of the head and neck revealed a metallic foreign body in the retropharyngeal area. However, since the patient was asymptomatic other than the complaint of foreign body sensation was noted, no further management was done and the patient was advised to follow-up after 3 months.[2]

Foreign body ingestion or impaction is commonly encountered in emergency room of the Department of Otorhinolaryngology-Head and Neck Surgery. This generally occurs in children between ages 6 months and 6 years.[3,4] Various presentations of patients with foreign body ingestion or impaction include vomiting, foreign body sensation, odynophagia, and dysphagia.

Ingested FB could be classified into certain types according to their features, including food bolus, blunt objects, sharp-pointed objects, long objects, and special objects (i.e., magnets, coins, and disk batteries).[3] Plain radiographs can be the most useful to investigate foreign bodies. Radiographs can demonstrate the location, number, size, and shape of foreign bodies. This may also exclude the presence of foreign bodies in airways in emergency situations. Due to increased density objects such as metal, glass and gravel are considered radiopaque, and multi-view, x-ray imaging is highly sensitive and specific when looking for these objects in soft tissues.[5] One limitation however is that some foreign bodies are not radiopaque subjects hence cannot be visualized in plain X-ray film. Any radiolucent foreign body may be located using an esophagogram or CT scan. [3]

In our case, two factors may have caused the further impaction of the foreign body. One would be due to the repetitive swallowing and vomiting of the patient while the foreign body was embedded in the posterior pharyngeal wall. Another would be due to the delayed extraction of the foreign body. In this case, the interval between the ingestion of the foreign body and its detection was approximately 5 days. Had the foreign body been extracted earlier, the further embedment of the foreign body may have been circumvented.

In the patient, rigid esophagoscopy missed the foreign body since it had impacted itself into the posterior pharyngeal wall and had already created a retropharyngeal sinus tract. Therefore, a careful inspection of this area should be done in cases where there is difficulty locating the foreign body especially if we are dealing with a sharp foreign body.

Approximately 80-90% of ingested foreign bodies pass through the GI tract spontaneously without complications, while 10-20% require endoscopic treatment and less than 1% require surgery. Possible complications of foreign body ingestion include impaction, perforation of the GI tract, mediastinitis which may eventually lead to death.[3] In this case, mediastinitis was a possible complication since the foreign body had been impacted in the retropharyngeal tract for approximately a week before it had been extracted. Abscess formation which may lead to mediastinitis would have also been a possible complication in the patient had the foreign not been extracted.

In our patient, the retropharyngeal tract mimicked fourth branchial cleft sinus tracts which start at the pyriform fossa. This sinus tract, unlike branchial cleft sinus tracts which extend anteriorly to the skin of the anterior neck, was parallel to the esophagus. A series of diagnostic esophagoscopies and neck soft tissue lateral radiographs did not show spontaneous closure of the tract. This may probably be due to the eventual mucosalization of the sinus tract and infection of the tract. Without spontaneous closure of the opening of the sinus tract, we adopted the management of 4th branchial cleft sinus tracts using endoscopic electrocautery to obliterate the sinus tract's opening and applied it to this case.

In 2004, retrospective chart review evaluating the effectiveness of endoscopic cauterization as a definitive treatment for fourth branchial cleft sinuses done by Verret and colleagues, revealed no recurrence with an average follow-up of 3 years.[7] A multicentric review from 1998 to 2016 of pediatric patients who presented with an endoscopically-confirmed fourth branchial pouch anomaly was done by Rossi et al in 2019. It was their goal to determine the epidemiology and the predictive factors of success of the surgical management, both open and endoscopic techniques, of fourth branchial anomalies. The aim of endoscopic cauterization was to obtain a synechia of the ostium of the fistula. Result revealed a success rate of 86.8%, with no reported complications.[8] In a systematic review done by Lachance et al in 2016, wherein they concluded that endoscopic management (in which electrocautery was the method that was predominantly done) appears to be a safe and effective technique as a primary option for treatment of piriform sinus fossa sinus tracts.[9] In our patient, endoscopic electrocautery was done on the opening of the retropharyngeal sinus tract achieving closure of the retropharyngeal tract.

An 8 month-old female who ingested a glass shard was presented. The ingestion of pointed or sharp objects may be embedded into the retropharyngeal space and its further advancement

may be caused by shearing forces caused by repetitive swallowing and vomiting. Immediate detection of these sharp foreign bodies may prevent formation of such tracts. Therefore, a high index of suspicion must be had in cases where foreign bodies that are not visualized by rigid esophagoscopy by careful inspection of the mucosal wall of the pharyngeal area with further guidance of radiographs. The innovation of endoscopic electrocautery as management of the sinus tract, inspired from the management of fourth branchial cleft sinus tracts, is an effective approach in management.

REFERENCES

1. Ziad, T., Rochdi, Y., Benhoummad, O., Nouri, H., Aderdour, L., & Raji, A. (2014). Retropharyngeal abscess revealing a migrant foreign body complicated by mediastinitis: a case report. *Pan African Medical Journal, 19.* doi:10.11604 /pamj.2014.19.125.5334
2. Mehta, A., Panwar, S., & Verma, R. (2004). Retropharyngeal Foreign Body. *Medical Journal Armed Forces India, 60(4), 390–391*. doi:10.1016/s0377-1237(04)80020-0
3. Feng S, Peng H, Xie H, Bai Y, Yin J. Management of Sharp-Pointed Esophageal Foreign-Body Impaction With Rigid Endoscopy: A Retrospective Study of 130 Adult Patients. *Ear, Nose, Throat Journal 1-8.* DOI: 10.1177/ 0145561319901033.
4. Fung B, Sweetser S, Wong Kee Song L, Tabibian J. Foreign object ingestion and esophageal food impaction: An update and review on endoscopic management. *World J Gastrointest Endosc 2019 March 16; 11(3): 174-192.*
5. Laya BF, Restrepo R, Lee EY. Practical Imaging Evaluation of Foreign Bodies in Children: An Update. Radiol. Clin. North Am. 2017 Jul;55(4) :845-867. [PubMed]
6. Khorana J, Tantivit Y, Phiuphong C, Pattapong S, Siripan S, Foreign Body Ingestion in Pediatrics: Distribution, Management and Complications. *Medicina 2019, 55(10), 686;* https://doi.org/10.3390/medicina55100686.
7. Verret D, McClay J, Murray A, Biavati M, Brown O. Endoscopic *Cauterization* of Fourth Branchial Cleft Sinus Tracts. *Arch Otolaryngol Head Neck Surg. 2004;130:465-468.*
8. Rossi M, Moreddu E, Leboulanger N, Akkari M, Triglia J, Mondain M, Nicollas R, Denoyelle F. Fourth branchial anomalies: Predictive factors of therapeutic success. *Journal of Pediatric Surgery 54 (2019) 1702–1707.*
9. Lachance S, Chadha N. Systematic Review of Endoscopic Obliteration Techniques for Managing Congenital Piriform Fossa Sinus tracts in Children. *Otolaryngol Head Neck Surg. 2016 Feb;154(2):241-6.* doi: 10.1177/ 0194599815613286. Epub 2015 Nov 2.
10. Wong P, Moore A, Daya H. Management of third branchial pouch anomalies – An evolution of a minimally invasive technique. *International Journal of Pediatric Otorhinolaryngology 78(2014) 493–498.*

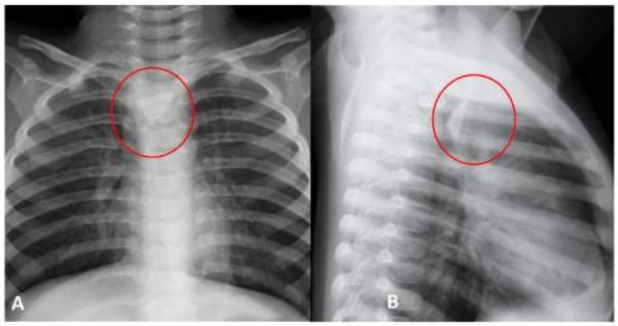

Figure 1. Plain Chest Radiograph. **A.** Anteroposterior view showing a triangular radiopaque object at the level of T1 and T2 **B.** Lateral view showing a triangular radiopaque object at the level of T1 and T2.

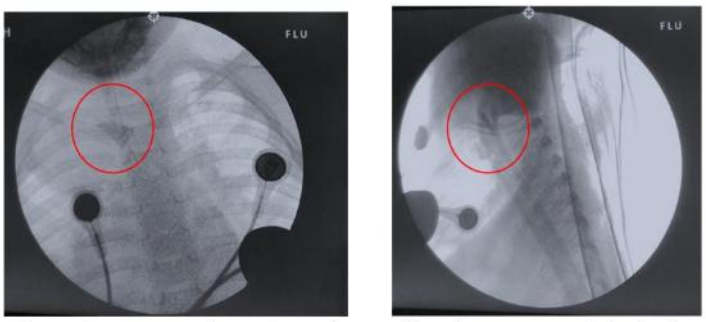

Figure 2. Intraoperative radiograph revealing the presence of the foreign body at the level of T1-T2

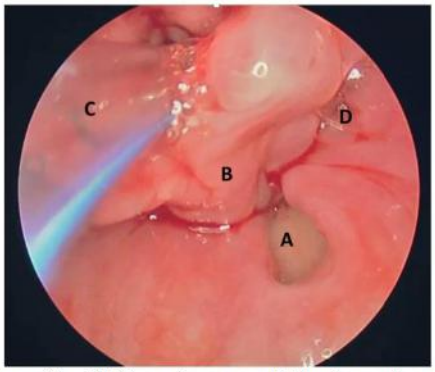

Figure 3. Rigid endoscopy of the hypopharynx revealing a linear wound in the retropharyngeal area. (A- opening to the retropharyngeal tract B-post-cricoid area arytenoid complex C- endotracheal tube D- pyriform sinus)

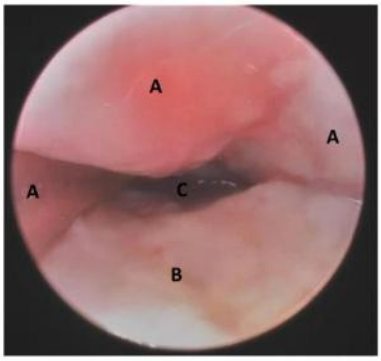

Figure 4. Rigid endoscopy of the retropharyngeal tract.(A- posterior pharyngeal wall B- prevertebral soft tissue C – lumen of retropharyngeal tract)

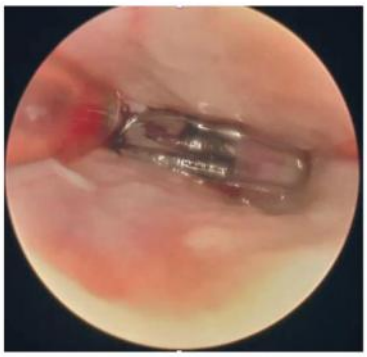

Figure 5. A glass shard at the end of the retropharyngeal tract.



Figure 6. A glass shard measuring 1.8 x 1.5cm

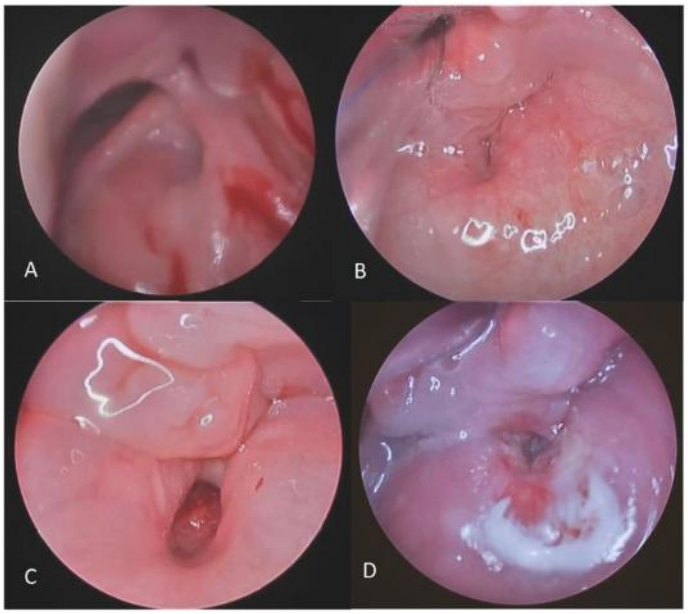

Figure 7. Series of diagnostic esophagoscopies post-extraction (**A**-Day 4 post-op, **B**-Day 19 post-op, **C**-Day 26 post-op, **D**-Day 32 post-op)

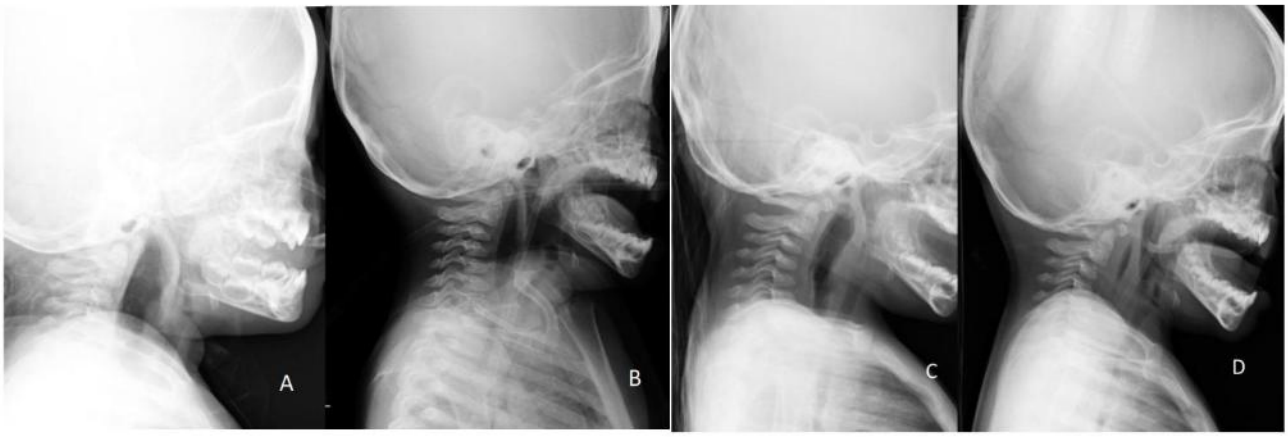

Figure 8. Series of neck soft tissue lateral radiographs post-extraction (**A**-Day 15 post-op, **B**-Day 21 post-op, **C**-Day 25 post-op, **D**-Day 32 post-op) There is persistence of retropharyngeal emphysema from post-operative Day 15 to 32.

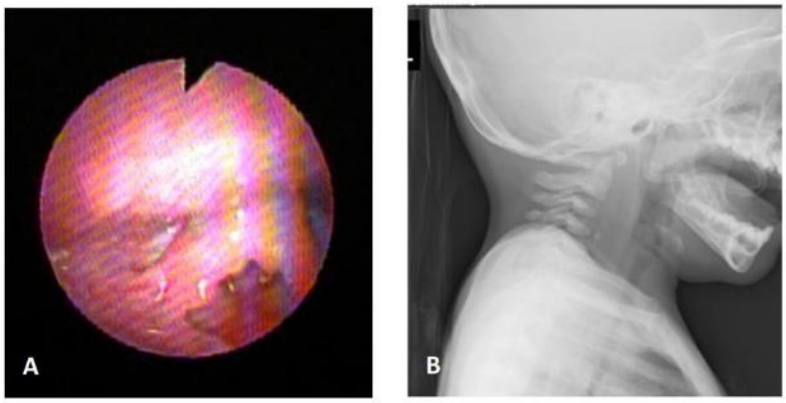

Figure 9. Obliteration of opening of the retropharyngeal tract 2 weeks postoperatively (**A.** flexible video endoscopy **B.** Neck soft tissue lateral)

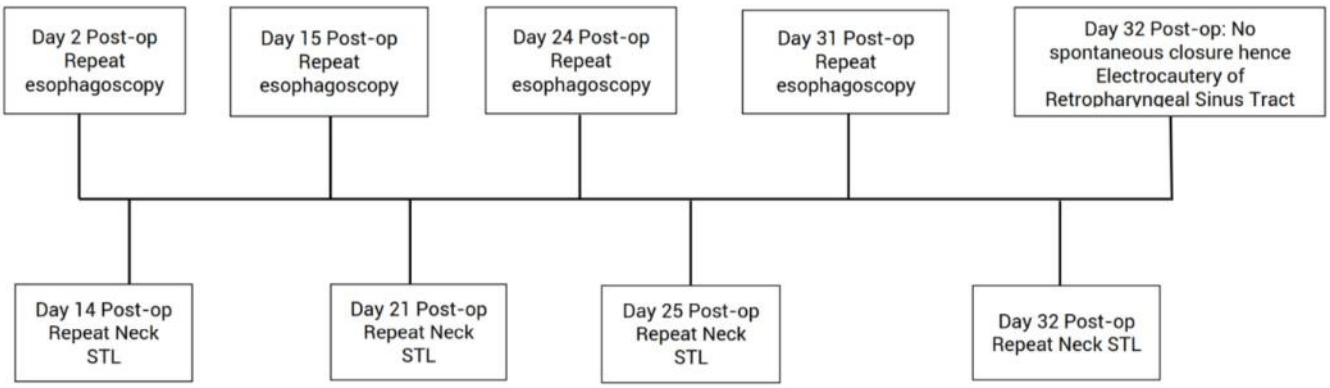

Figure 10. Timeline of series of diagnostic rigid esophagoscopies and neck soft tissue lateral leading to subsequent electrocautery of the opening of the retropharyngeal tract

Orthotic Management with a Customized Humeral Brace for Gorham-Stout Disease of the Humerus: A Case Report*

Margaux Mae M. Rayos, MD[1]

ABSTRACT

Gorham-Stout disease is characterized by massive osteolysis or "vanishing bone" on radiograph. Due to its rarity, no standard Physical Medicine and Rehabilitation (PM&R) management has been published. With this comes the dilemma of managing another case of vanishing right humerus in a 13 year-old male, right handed student, with normal growth and development. To date, this could be the third documented case in the Philippines, but the first with humeral involvement, and the first to manage using a customized humeral brace. The absence of the right humerus affects the bimanual overhead and tabletop activities of the patient, for which a custom-made humeral orthosis was provided to manage the limited activities. There were improvements in activities such as writing, card turning, stacking, and lifting objects of variable weights, as well as with hand dexterity as evidenced by the standardized hand function tests done prior and post brace fitting. Being a rare bone disease with no standard management and unpredictable course, cases are managed symptomatically. For this case of an absent humerus significantly affecting upper extremity function, orthotic management is one aspect that could be recommended to achieve positive functional outcomes.

Keywords: Gorham-stout disease, massive osteolysis, disappearing bone disease, idiopathic multicentric osteolysis, orthotics, braces

INTRODUCTION

Gorham-Stout disease (GSD), also known as vanishing bone disease as well as idiopathic massive osteolysis, is a rare disease with its cause remaining to be obscure, but is most often characterized by endothelial proliferation of lymphatics and vessels or progressive dissolution of contiguous osseous structures where no regeneration is noted following the osteolysis.[1] Apart from its etiology being unknown, its course has also been reported to be unpredictable based on the limited studies available. Most reports have shown that the usual presentation starts with pain, subsequent swelling, and gradual functional impairment of the affected region. One reported case was diagnosed after a pathologic fracture.[2,3]

The prognosis of patients with GSD, like its course, is also unpredictable and diverse. The following factors affect its prognosis: extent of the bone resorption, the specific involved part and their related structures. With regards to management, there is presently, no consensus in the medical literature on what is the most effective treatment, and more often, the treatment is directed towards specific symptoms.[4]

We report a first case of idiopathic massive osteolysis of the humerus in the country as well as the first reported case of orthotic management using a customized humeral brace with the aim of improving upper extremity function and activities of daily living.

CASE

Patient Information

A 13-year old male, left handed student, was previously diagnosed with probable idiopathic massive osteolysis of the humerus, otherwise known as Gorham-Stout disease on the basis of a history of bone pain, swelling, and limitation of range of motion of the right arm with no precedent infection and a radiograph showing absence of the right humerus. The child was well until he was diagnosed with humeral fracture following an unreported fall at age 5 in 2010. Consultation was done when his hand started to swell and progressively affecting the right shoulder. On follow

*1st Place, 2020 Philippine Medical Association Case Report Presentation, September 7, 2020
[1]Resident, Department of Rehabilitation Medicine, Philippine General Hospital

up, there was no note of callus formation on radiograph of the right humerus. In the interim since initial consult, radiographs of the right humerus revealed progression of osteolysis and no signs of bone healing. He could no longer move his right shoulder fully which primarily became the point of concern for the patient and the family. There was no note of any family history of bone disease or cancer.

Clinical Findings

Over time, there was noted decreasing muscle bulk of the deltoid, trapezius, and triceps and further reduction of right shoulder range of motion and documented resorption of the right humerus, affecting the patient's activities that required overhead reaching.

Timeline

Diagnostic Assessment

Work ups revealed no signs of infection, nor endocrine and renal dysfunctions. He was lost to follow up after the diagnosis of idiopathic massive osteolysis of the right humerus was made.

Serial radiographs showed continuous resorption of the right humerus (Figure1).

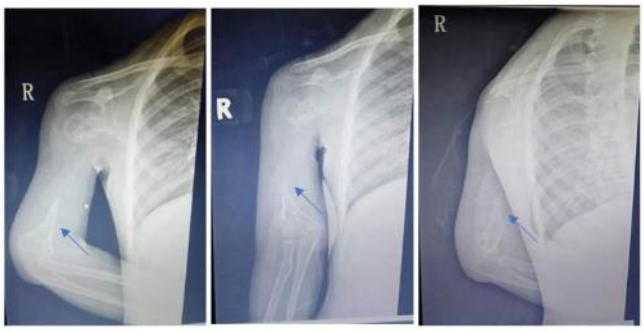

Figure 1a Figure 1b Figure 1c
"Rat-tail" appearance of the remaining humerus (1a Antero-posterior view with right elbow flexed, 1b with elbow in neutral position, 1c with elbow flexed and adducted)

Therapeutic Intervention

The limitations in doing overhead activities with his right shoulder prompted consultation for possible orthotic management. He was seen by both orthopedic surgeon and pediatrician. Both specialists did not consider surgical management, radiotherapy nor anti-resorptive medications.

The patient adapted to his impaired right humeral function with the use of one hand technique in carrying simple tasks although requiring proper positioning of the wrist. He was subsequently referred to study hospital in December of 2019 for possible fabrication of a brace. On initial consult, the following findings were noted: reduced muscle bulk on the right deltoid and right trapezius and upper limb length discrepancy, the left being longer by 12 cm (right = 65 cm and left = 77 cm). The patient was prescribed with a modified humeral brace with the following components: rigid polyethylene shell covering the whole arm with extension to the elbow with 45 degree angulation, with closed-cell foam lining, three Velcro straps, and three point harness (Figure 2). The standard humeral brace was modified to extend the upper trim line to anchor at the level of the clavicle to limit the motion at the shoulder to prevent traction injury. Since the patient was able to flex and extend his elbow as long as the elbow is supported, another modification was to extend the distal trim line up to the elbow to keep the elbow flexed at 45 degrees.

Follow-up and Outcomes

Objective functional tests including Jebsen Taylor Test of Hand function and Minnesota Manual Dexterity Test were used to assess his level of hand functioning.

Figure 2a (anterior) Figure 2b (posterior) Figure 2c (lateral)

The functional tests were done pre- and post-fabrication of the brace with noted improvements in terms of efficiency of performance, specifically in writing, card turning, lifting small objects, feeding, stacking, lifting objects of varying weights, with some observations of use of compensatory strategies such as shoulder elevation and tip-toeing, particularly in reaching objects past arm's length due to absence of elbow extension. The scores for each test are presented in Appendix A and Appendix B.

The functional tests were done pre and post fabrication of the brace with noted improvements in terms of efficiency of performance, specifically in writing, card turning, lifting small objects, feeding, stacking, lifting objects of varying weights, with some observations of use of compensatory strategies such as shoulder elevation and tip-toeing, particularly in reaching objects past arm's length. For the patient, results revealed minimal improvement with the use of customized humeral brace in turning but not in placing subtests where the results showed the patient was faster by 14.1 seconds (s) in turning subset with the use of the brace. However, based on the norms, even prior to using the brace, the patient's average scores in terms of gross manual dexterity were within normal limits. Applying this to our patient, with the elbow secured in a functional position, eliminating the need to secure it with a sling, or with the other hand, or by placing the elbow on top of the table, the patient would be able to perform activities such as writing, turning, lifting and stacking objects, while making sure the shoulder is secured from injury. There were no adverse events reported on the use of the orthosis.

DISCUSSION

Gorham's disease is a rare disorder that may affect any part of the bone, but it most commonly involves the skull, rib, pelvic girdle, and shoulder.[5] As of recent literature, there is no standardized treatment and results are unpredictable as is the prognosis. In one study, an 18 year old male diagnosed with the disease manifesting on his humerus, was managed with an autogenous vascularized fibular graft with wide excision and followed up after 10 years, and showed evidence of bone union and no signs of osteolysis which could be another avenue worth pursuing with research.[6] With this case where no surgical intervention was done or contemplated by the patient's pediatric orthopedic surgeon, non-surgical and non-radical management was sought as compared with the few existing literature on Gorham-stout disease. The primary goal of the patient and the family was to have improvement in function using non-surgical means, of which, the modified humerus brace was able to provide in terms of improvement in performing activities of daily living that require overhead activities such as grooming, bathing, reaching, lifting objects, writing on the board, as well as in some active play and games. To the best of knowledge, there has not been any documented report on the role of an orthosis in managing the specific case.

Given the unpredictable nature of the disease, depending on the affected bone, its attachments and its functions, there could be a need to support, align, prevent, or correct deformities and improve function of the moveable parts of the body in which, orthotic management would address. It is recommended that upon identification of the bony structure that has undergone massive osteolysis, to consider whether there is a need to provide an external structural support to prevent further deficit or injury.

To conclude, Gorham's disease is a very rare bone disease that has proven to be a challenge not only in diagnosis, but also with its management and prediction of its course and most often monitored from initial suspicion and throughout their lifetime. While there is still a need to explore the reported management in literature which include surgery, bone grafts, radiotherapy, and bone resorption inhibitors such as bisphosphonates, the treatment goals of the above mentioned approaches would still be symptomatic as well as to aid in preventing further progression of the osteolysis. Other problems that need to be addressed are the personal and psychosocial factors especially since the patient was fully functioning prior to the injury. Specifically, body image issues and how the impairment affects present and future status in current home, school and or future employment status of the patient, and how the patient and his family can accept the unpredictability of their disease. Apart from the mentioned medical and surgical treatments, early rehabilitation can be offered in terms of physical therapy, occupational therapy and psychology counseling to address the deficits, modifications at home, school, work environment, psychosocial intervention, and in this case, orthotic management. For this case, orthotic management, a safe, non-invasive, supportive management, has alleviated the patient's impairments, and thus, improvement of his performance of activities of daily living requiring overhead arm functions. Therefore for other similar cases, an appropriate orthosis is an option to correct or reverse functional deficits to achieve positive functional outcomes. Regular monitoring and anticipatory management of a pediatric patient using patient-centered multi-disciplinary team approach is warranted.

INFORMED CONSENT

Informed consent from the parent and assent from the patient were obtained with purpose, anonymity, risks and benefits explained.

REFERENCES

1. Noman S, Faiz S, Khan SA, Sattar A. Massive osteolysis in distal shaft of humerus: A case report on vanishing bone disease. J Coll Physicians Surg Pak. 2018 Sep;28(9):S164-S165. doi: 10.29271/jcpsp.2018.09.S164.

2. Heffez I, Doku H, Carter B, Feeney D. Perspectives on massive osteolysis: Report of a case and review of the literature. J Oral Surg, Oral Med, Oral Path. 1983;55(4):331-43.

3. Nikolaou, V, Chytas D, Korres D, Efstathopoulos N. Vanishing bone disease: A review of a rare entity. World J of Ortho. 2018 Nov;5(5):694-8.

4. Blei, F, Dellinger, M, Kelly, J. Gorham-Stout Disease. National Organization for Rare Disorders. Accessed: 5/20/19 available from https://rarediseases.org/rare-diseases/gorham-stout-disease/

5. Priemel M, Kuhlmey W, Delling A. The Gorham-Stout syndrome. A report of six cases with histopathological findings. J Bone Joint Surg. 1999;81(3);501-6.

6. Kim J, Kang H, Kim D, Shin C. Gorham's disease in humerus treated with autogenous vascularized fibular graft. Ind J of Ortho. 2017 Mar-Apr; 51(2):217-21.

7. Garingarao C, Sandoval M. The case of the missing wrist: a probably case of idiopathic osteolysis. BMJ Case reports. 2013 September: bcr2013200853

Appendix A. Jebsen Taylor Test of Hand Function with and without Humeral Brace

Jebsen Taylor Test of Hand Function				
	With sling	Without sling or custom-made humeral brace	With custom-made humeral brace	Normative values
Writing	42.79 (manuscript) 56.49 (cursive)	39.09s (in cursive)	35.53s (in cursive)	12.2±3.5
Card turning	12.32s	6.92s	6.32s	4.0± 0.9
Lifting small objects	12.5s	9.43s	12.50s	5.9±1
Stacking checkers	7.15s	7.53s	5.98s	6.4±0.9
Lifting large heavyweight objects	9.20s	9.27s	8.23s	3.3±-0.7
Lifting large lightweight objects	6.45s	7.18s	6.35s	3.0±0.4
feeding	12.52s	27.39s	23.27s	3.0±0.5

*s-seconds

Jebsen Taylor Test of Hand Function

The test assesses a broad range of uni-manual hand functions required for activities of daily living divided into 7 subtests performed on both non-dominant and dominant hands with the maximum time allotted per subtests being 120 seconds. The lower the score, the greater the function, and speed, not quality of performance is measured.

Appendix B. Minnesota Manual Dexterity Test with and without Humeral Brace

Minnesota Manual Dexterity Test			
	Without sling or custom-made humeral brace	With custom-made humeral brace	Normative range
Placing	105.84s	119.94s	100-200s
Turning	56.115s	54.995s	60-90s

The Minnesota Manual dexterity test is used to measure a subject's simple but rapid eye hand coordination as well as arm-hand dexterity. In general, it measures gross motor skills. The faster the patient is able to complete a task, the better the dexterity.

Complete Mid-Superior Sagittal Sinus Transection*

Cheryl Joy B. Biado, MD[1]

ABSTRACT

Foreign body impalement and subsequent penetrating head injury is uncommon in clinical practice hence no standard management protocol is available for such cases. Additionally, injury to the superior sagittal sinus is one of the most significant event even in neurosurgery due to the probability of massive blood loss at the time of trauma or surgery resulting in a high mortality rate. This report, presents a case of penetrating brain injury with a metal rake crossing the skull bone with entry point in the parietal bone along the midline transecting through the posterior 2/3 of the superior sagittal sinus with the tip situated just before the body of the corpus callosum. The foreign body was removed which resulted to massive bleeding, uncontrolled by suture ligation, chemical and heat coagulation. Bleeding was managed by digital compression and packing using gelfoams and cottonoids with noted favorable outcome.

KEYWORDS: Foreign body impalement, head trauma, metal rake, penetrating injury, superior sagittal sinus.

INTRODUCTION

Foreign body impalement to the brain though extremely uncommon, is significant due to the challenge of the uniqueness of the involved areas and its presentation, and that there is no existing standard management protocol for such cases. On top of this, traumatic involvement of dural venous sinus is one of the most noteworthy cases even in neurosurgery due to the probability of massive blood loss at the time of trauma or surgery resulting in a high mortality rate during the perioperative period even in the absence of a notable hematoma. Of all head injuries, significant dural sinus injury occurs in 1.5-5% of these cases, with injury to superior sagittal sinus in 70-80%[1]. In this case report, we present a case of penetrating head injury with a metal rake involving the superior sagittal sinus, the surgical challenges and clinical outcome after its successful removal.

CASE REPORT

This is a case of a 26 year-old male with known case of schizophrenia, who presented to our emergency department with impaled foreign body, a metal rake, in the mid-parietal region, allegedly self-induced, few hours from consult. The patient was GCS 14 (E4V4M6), drowsy but easily arousable, calm, with monosyllabic answers to questions, and follows simple commands at the time of examination. Vital signs were stable and within normal limits with BP of 130/80 mmHg, CR of 84 bpm, RR of 21 cpm, temperature of 37 degrees Celsius and SPO2 of 97%. There was no active bleeding coming from the impalement site. Pupils were 2-3mm, equally reactive to light. No noted sensory deficits, but with noted paresis on right lower extremity. The patient was kept flat on bed; prevention of unnecessary displacement of the impaled foreign body, as well as escape, suicide and assault precautions were instituted. Patient was given tetanus prophylaxis and started on broad spectrum antibiotics.

Skull APL showed penetrating foreign body into the skull. CT scan and CT angiogram of the head showed penetrating brain injury with a sharp metallic object crossing the skull bone with entry point in the parietal bone along the midline through the sagittal suture. The tip is situated just before the body of the corpus callosum. The adjacent brain

*2nd Place, 2020 Philippine Medical Association Case Report Presentation, September 7, 2020
[1]Resident, Department of Surgery, Ilocos Training & Regional Medical Center

parenchyma cannot be adequately assessed due to streak artifacts. The penetrating object appears to pass through the mid-sagittal sinus. Dilated cortical veins noted predominantly in the frontal region. Unremarkable circle of Willis.

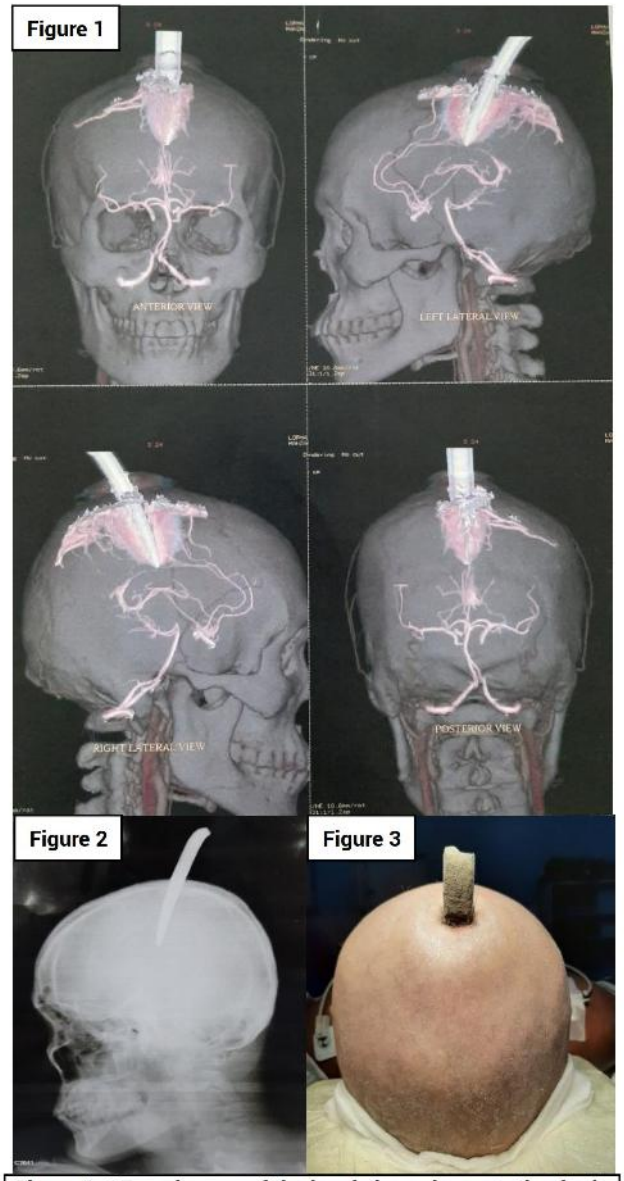

Figure 1. CT angiogram of the head showed penetrating brain injury with a sharp metallic object crossing the skull bone with entry point in the parietal bone along the midline through the sagittal suture. The tip is situated just before the body of the corpus callosum. The adjacent brain parenchyma cannot be adequately assessed due to streak artifacts. The penetrating object appears to pass through the mid-sagittal sinus. Dilated cortical veins noted predominantly in the frontal region. Unremarkable circle of Willis.

Figure 2. Skull APL showing penetrating foreign body into the skull.

Figure 3. Impaled metal rake in the mid-parietal region

The dilemma at this time was whether to operate on the patient to remove the foreign body and risk the possibility of massive bleeding from the sagittal sinus or to retain the foreign body in-situ but with the possible consequences of infection or undue dislodgement and terrible demise. After thorough assessment and weighing of the benefits and the consequences, we proceeded with the removal of the foreign body. The patient was prepared for immediate surgery. Patient was intubated and put under general anesthesia. He was placed into prone position to provide adequate exposure of the parietal region. Markings, asepsis and antisepsis were done. An I–shaped incision was made around the foreign body, at midline, over the sagittal suture. Craniectomy was done on the parietal bone surrounding the impaled object while ensuring non-displacement of the foreign body as to avoid bleeding and trauma to the sagittal sinus.

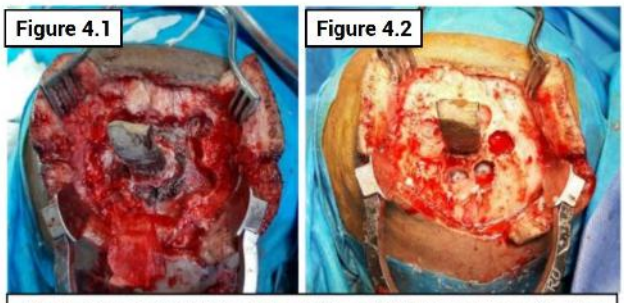

Figure 4 Craniectomy was done on the parietal bone surrounding the impaled object while ensuring non-displacement of the foreign body as to avoid bleeding and trauma to the sagittal sinus.

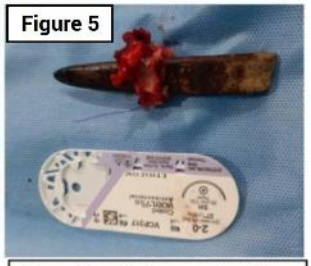

Figure 5. Metal rake measuring 15 cm x 2 cm x1 cm removed from the brain parenchyma

The foreign body was then carefully removed along with the attached bone fragments exposing a 2 cm transection along the posterior 2/3 of the superior sagittal sinus and underlying brain parenchyma which was accompanied by massive bleeding. Suture ligation, chemical and heat coagulation of the dural sinus defects were

attempted but massive, uncontrolled bleeding still ensued. Hence, digital compression followed by packing of the dural sinus defect using gelfoams and cottonoids were done. Layer by layer suturing of the galea up to the skin was done over the packing. Patient was maintained under permissive hypotension along with adequate blood transfusion during and after the operation. The patient was admitted to surgical ICU for close monitoring post-operatively. Patient was stable and extubated on post-operative day 1. Antibiotics and antipsychotic medications were continued. Daily wound care and neuro rehabilitation was provided. Repeat CT-scan of the head post-surgery, revealed minimal subarachnoid hemorrhage. Patient was subsequently discharged, improved, with minimal motor weakness on right lower extremity after two weeks of treatment and rehabilitation.

On follow up, one month post injury, patient was GCS 15, conversant, coherent and not in distress. He has no complaints of headache, dizziness, slurring of speech, blurring of vision, sensory deficit or seizures; still with residual weakness on right lower extremity with muscle strength of 4/5, but able to ambulate with minimal support.

Magnetic resonance venography was done revealing complete flow gap at the posterior 2/3 of superior sagittal sinus and a prominent vein of Trolard. This connects the SSS and the vein of Sylvius which preventing another fatal complication of venous infarct and subsequent death.

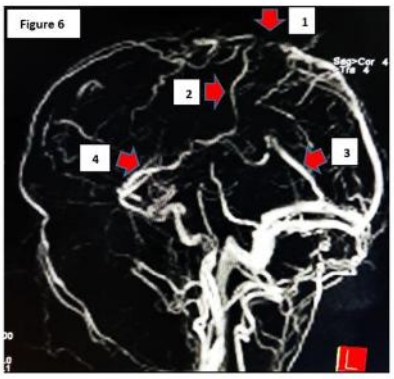

Figure 6. MRV showing flow void (1) at the transected area. The vein of Trolard (2), Vein of Labbe (3), including Middle Cerebral Vein (4) are all prominent.

CASE DISCUSSION

The superior sagittal sinus (SSS) is a dural venous sinus in the sagittal groove, beginning from foramen caecum and terminating at the confluence of sinuses where it merges with the straight sinus and corresponding transverse sinus.[2]It is the largest among the dural sinuses, triangular in section, narrow in front, and gradually increases in size as it passes backward.[4] The SSS is strictly avoided during neurosurgical procedures such as craniotomy due to its propensity for massive, uncontrollable bleeding which may lead to intraoperative mortality hence minimum SSS to bone flap distance of 20 mm is recommended.[5,6] Traumatic dural venous sinus injuries are rare and mostly unreported due to its high mortality rate. The incidence of traumatic dural sinus injuries ranges between 4 - 12% at times of war and about 1% in peace time, with a high mortality rate of about 41%. [7]In a study conducted from January 1999 to December 2014, there were only 20 patients with a dural venous sinus injury out of the 1,200 patients with severe head injuries who underwent neurosurgery in their institution. Literature search revealed claims of dural sinus injuries reported but a case of major injury to the superior sagittal sinus has not been cited thoroughly. In a case report, a nail gun injury resulted in damage to the lateral edge of the superior sagittal sinus which was treated via a parasagittal craniotomy and suturing of the hole in the inner superior sagittal sinus leaflet.[8]Another case report of alleged SSS injury, with the tip of the nail penetrating the right ventricle, but angiography showed that the nail was only very close to the SSS and that the venous flow was normal. The nail was removed without bleeding and injury to SSS.[9]

The incidence of penetrating dural sinus injuries is rare, and to date, not many relevant studies have been published worldwide.[10] Of the few published studies, some are even controversial, hence treatment guidelines for dural sinus injury are still yet to be established. Penetrating intracranial foreign bodies can be managed on a case by case

basis. Surgical removal of the foreign body may cause secondary brain parenchyma and vascular injuries, but without the removal of the foreign body, the patient would have been at increased risk for morbidity and mortality due to bleeding from the sagittal sinus, increasing intracranial pressure, or infections.[11] In this case, the large transection of the superior sagittal sinus which resulted to massive bleeding upon removal of the foreign body which was uncontrolled by conventional suture ligation or coagulation techniques was effectively managed by packing of the dural sinus defect using gelfoams and cottonoids. Our case demonstrated how the basics of trauma such as direct pressure packing along with systemic vascular control is also effective in managing massive hemorrhage even in rare traumatic neurovascular injuries. Another major factor that contributed to the very good outcome in the prognosis of the patient are the major veins: Trolard, Labbe and Middle Cerebral Vein. These promoted good venous drainage from the affected cortical territories thereby preventing gross venous infarcts and ischemia which could lead to catastrophic outcome for the patient.

SUMMARY

Penetrating brain injury resulting to transection of superior sagittal sinus is highly fatal and requires prompt management. The dilemma vis-à-vis removal and conservative management of penetrating foreign body in the brain is vital, but surgery in penetrating Traumatic Brain Injury is still the treatment of choice if possible. Pre-operative planning with the aid of imaging is essential for the success of surgery. More importantly, this case demonstrated how the basics of trauma such as direct pressure packing along with systemic vascular control is also effective in managing massive hemorrhage even in rare traumatic neurovascular injuries with noted favorable outcome.

ACKNOWLEDGEMENT

This case presentation was not supported nor funded by any organization or institution. This case presentation is made purely for the reporting of the presented interesting case to the Department of Surgery of Ilocos Training and Regional Medical Center and as a submission to the paper presentation and call for papers of the said institution.

Mayer-Rokitansky-Küster-Hauser Syndrome*

Miracle Faith H. Emano, MD[1]

ABSTRACT

Mayer-Rokitansky-Küster-Hauser (MRKH) Syndrome is a rare disease found in 1:4,000-5,000 live female births. It presents with vaginal and uterine agenesis in females. Ultrasound of the pelvis is the initial imaging of choice. Pelvic Magnetic Resonance Imaging (MRI) is the gold standard to confirm the presence of a rudimentary uterus. Surgical and nonsurgical options to create a neovagina may be offered to the patient. Counselling of patients is necessary.

This report presents a case of a 15-year old phenotypic female with cyclic abdominal pain subsequently noted with absent vaginal canal. Ultrasound and MRI of the pelvis showed the absence of a uterus and upper vagina with intact ovaries. Karyotyping showed 46, XX, confirming that the patient is a female. Analgesics were prescribed for the abdominal pain. Regular counselling was provided by Adolescent Medicine.

Keywords: vaginal agenesis, uterine agenesis, primary amenorrhea, adolescent

INTRODUCTION

Mayer-Rokitansky-Küster-Hauser syndrome (MRKH), or Müllerian agenesis was first described by German anatomist and physiologist Mayer in 1829 as part of multiple congenital anomalies among four stillborns. In 1961, the term "rudimentary solid septate uterus with solid vagina" was coined as the Mayer-Rokitansky-Küster Syndrome by Hauser.[1] Hauser and Schreiner studied this further and emphasized the importance of distinguishing between Müllerian agenesis and testicular feminization (androgen insensitivity), both of which present with vaginal atresia.[2]

This report presents a case of a patient with MRKH presenting as recurrent hypogastric pain. Clinical presentation, diagnosis, pathophysiology, and management of MRKH will be discussed.

CASE REPORT

A 15-year old female, Filipino, presented with cyclic hypogastric pain. History started eight months prior, when she complained of crampy, non-radiating hypogastric pain, with pain scale of 8 out of 10 in severity lasting 2 hours for 2 days each month. The pain spontaneously resolved with rest. There were no associated fever, abdominal distention, vomiting, or bowel and bladder changes. It interfered with her school activities leading to frequent missed school days.

The monthly occurrence of abdominal pain prompted consult with a general pediatrician and was referred to a gynecologist. Physical examination revealed an absent vaginal canal. Transrectal ultrasound showed prepubertal anteverted uterus with thin endometrium (Appendix A). She was assessed as a case of imperforate hymen and was advised surgery. They went to a tertiary pediatric hospital for further evaluation and counselling.

Thelarche and pubarche were at 12 years of age. Axillary hair and acne were noted at 13 years of age. She has had no menarche. She denies history of oral contraceptive intake. There was no note of excessive facial hair or deepening of voice. She is a nulligravid with no prior sexual encounters. She had expressed desires to have a family of her own in the future. All the females in their family have a history of menstruation and are able to bear children. There was no known family member with a similar case as the patient.

*3rd Place, 2020 Philippine Medical Association Case Report Presentation, September 7, 2020
[1]Resident, Philippine Childre's Medical Center, Quezon City

Upon examination, the patient was seen awake and not in cardiorespiratory distress. She had stable vital signs and reported no pain at the time of examination. Her weight is 38 kg, and she is 155 cm tall ($z < 0$), with a normal BMI for age of 15.8 kg/m^2 ($z = -2$). The abdomen was flat with normoactive bowel sounds and tympanitic on percussion. There were no palpable abdominal masses, organomegaly, or tenderness. On gynecologic examination, the patient was noted to have a grossly normal female external genitalia with no discharge or bleeding (Appendix B). Pubic hair was present. The vaginal canal could not admit a cotton swab. The Sexual Maturity Rating (SMR) was stage 3 for pubic hair and stage 3 for breast.

She was seen at the General Pediatrics outpatient department (OPD), assessed as a case of imperforate hymen. She was then referred to Pediatric Gynecology service for further assessment and management. Rectal ultrasound showed prepubertal uterus, multicystic both ovaries, no adnexal masses, no hematometria, and no free fluid in the cul-de-sac (Appendix C). Vaginal agenesis was considered, hence pelvic Magnetic Resonance Imaging (MRI) and karyotyping were requested. The patient was prescribed with ibuprofen and celecoxib for the hypogastric pain.

Pelvic MRI plain and contrast findings showed no normal-looking uterus or cervix, with a consideration of agenesis, with multi-cystic ovaries, bilateral and no gross pelvic masses (Appendix D). Karyotyping showed 46, XX, normal female karyotype (Appendix E). The impression was MRKH syndrome. She was advised for close follow-up and to continue analgesics as needed. She was referred to Adolescent Medicine for counseling. Plans for surgical management were discussed.

CASE DISCUSSION

Evaluation of abdominal pain in adolescent females is challenging. A thorough history and physical examination narrows down the differentials. The initial step to the diagnosis is to obtain from the history the duration, frequency, location, and intensity of abdominal pain. Patients with acute abdominal pain usually presents with a single episode that may last from hours to days. On the other hand, patients with chronic abdominal pain typically complains of pain that lasts from days to months.[3]

Reported was a female adolescent who complained of crampy, cyclic abdominal pain lasting for eight months. Location of chronic abdominal pain in a female adolescent will limit the differential diagnoses. In this case, the abdominal pain was confined to the hypogastric area. Organic causes of hypogastric pain may involve the intestinal, urinary, reproductive, and muscular systems. A gastrointestinal, urinary, or infectious cause was least likely in the absence of bowel or bladder changes, and fever. Muscular strain is excluded given a negative history of trauma or exertion. Pregnancy was considered as the patient was of reproductive age. However, this is improbable with the history of amenorrhea.

The American College of Obstetrics and Gynecology defines primary amenorrhea as the absence of menarche by age of 15 years or within 3 years of thelarche.[4] An evaluation for primary amenorrhea is warranted in this patient as she was amenorrheic for 3 years after thelarche at the age of 12.

Evidence of female secondary sexual characteristics indicates normal functioning hormones. Therefore, the likelihood is low for a hypothalamic, pituitary, or ovarian problem. Several differentials may be considered in a patient presenting with primary amenorrhea and normal secondary sexual characteristics.

Androgen insensitivity syndrome (AIS) is a mutation of the gene for androgen receptor. The complete form of this disease affects genotypic males and presents with female external genitalia, blind vagina, absent uterus and adnexa, and undescended testes.[5] Patients with AIS do not grow axillary or pubic hair differentiating it from patients with MRKH syndrome. Further evaluation with medical imaging is necessary to determine the presence and type of gonads as well as abnormalities in the uterine and vaginal outflow tract.

Ultrasonography is the first-line diagnostic imaging test for the identification of pelvic structures. It may or may not identify anomalies of other pelvic organs that are associated with MRKH syndrome.[2] It has a sensitivity of 44%, and a high specificity of 98%.[6] Pelvic MRI can determine exact anatomic characteristics of MRKH syndrome. It has a sensitivity of 81% and specificity of 100%.[7] It is performed when ultrasound findings are inconclusive. MRI provides an accurate evaluation of uterine aplasia and a clear visualization of the rudimentary horns and ovaries.[8] In this case, pelvic MRI confirmed uterine and vaginal agenesis with the presence of ovaries.

Karyotyping identifies the patient's genotype and conclusively differentiates between AIS and MRKH syndrome.[5] The patient in this case had normal female 46, XX karyotype. With the findings of normal female secondary sexual characteristics and radiographically confirmed uterine and vaginal agenesis, the diagnosis of MRKH Syndrome was concluded.

Patients with MRKH syndrome have normal female phenotype, thelarche, pubarche, and karyotype (46,XX) but present with primary amenorrhea. The extent of malformations in MRKH syndrome varies widely. There are three classifications of MRKH.[9,10] Typical MRKH (Type I) presents with isolated utero-vaginal agenesis and is the most common among the types.[1] Atypical MRKH (Type II) exhibits utero-vaginal agenesis with asymmetrical malformations of the fallopian tubes, ovaries, or renal systems. The third type is Müllerian aplasia, Renal aplasia, and Cervico-thoracic Somite dysplasia (MURCS). Other ancillary tests may be done to identify the presence of anomalies commonly associated with MRKH syndrome. The patient did not clinically present with other anomalies, therefore she was classified as having typical or Type I MRKH.

Since 1917, there have been only three practice- or hospital- based studies on the prevalence of MRKH syndrome estimating it at around 1 in 4,000-5,000 females.[11,12,13] In the ICD-10 registry, the diagnosis of MRKH syndrome does not have its own category. Instead, it belongs under the codes Q51.0 (agenesis and aplasia of uterus) and Q52.0 (congenital absence of vagina). The Philippine Pediatric Society registry reported 3 cases of congenital absence of vagina and 4 cases of agenesis and aplasia of the uterus.[14]

The maturation of the female reproductive organs is a complex process that can be summarized into three stages: Müllerian duct formation, Wolffian duct regression, and Müllerian duct differentiation. By the 8th week of gestation, the Sex-determining Region Y (SRY) gene triggers androgen and anti-Müllerian hormone production in male gonads. This suppresses the Müllerian ducts and stimulates the Wolffian ducts to produce a male phenotype. In the absence of the SRY gene, the Müllerian duct is uninhibited and triggers differentiation to the uterus, fallopian tubes, cervix, and vagina.[15] MRKH syndrome is an anomaly in the Müllerian duct differentiation of the female reproductive organs. The etiology of MRKH syndrome is not fully understood. However, there have been studies on the genetic abnormalities that contribute to its development, such as ESR1, OXTR, HOXA10, and HOXA 13.[15] There is no definite or specific gene known to be involved in MRKH.

Patients with MRKH syndrome may present with cyclic abdominal pain. This is commonly due to a functioning endometrium in a rudimentary uterus. Another consideration is endometriosis via a metaplastic process in peritoneal mesothelium or ovarian surface endothelium referred to as coelomic metaplasia.[17] The cyclic hypogastric pain in this case may be interpreted as menstrual cramps. Nonsteroidal anti-inflammatory drugs (NSAIDs) are appropriate as first-line treatment.[18]

MRKH syndrome has implications to a woman's self-esteem. The diagnosis should be disclosed sensitively. Counselling and psychological support is important at the point of diagnosis and thereafter.[19] Infertility was found as the hardest psychological aspect of the condition to accept. This should be acknowledged during disclosure and services should be offered in exploring and alleviating such issues.[20] A multidisciplinary team approach involving the General Pediatrician, Adolescent Medicine, Psychiatry, and Gynecology services is ideal.[19]

The patient is at middle adolescence. Counseling is centered on the individuation process where self-identity is established. During these sessions, normality in the sexual body is discussed as well as the implications of her condition on the impairment to experience sexual pleasure, to sexual intercourse, and to conceive children. As she proceeds to late adolescence, she is guided to

progressively accept her condition through intellectualization. Acquiring more knowledge about her condition allows her to feel more in control. As the patient is transitioning to adulthood, a supportive network should be established, composed of adult family members, peers, and health care providers.[19]

Risks and benefits of surgical interventions are discussed once the patient is psychologically fit to undergo surgical intervention. Treatment options for MRKH syndrome include vaginal dilation as the first line management for vaginal agenesis. This procedure has a success rate of 75-85%.[21,22] Minimally invasive advances have been developed in creating a neovagina. Two of the most common procedures being practiced today are the Vecchietti and the Davydov procedure.[23,24]

MRKH syndrome has great impact on fertility. Before the advent of reproductive technologies, patients were limited to adoption.[25] In Vitro Fertilization (IVF) and surrogacy are some relatively new options that can be explored. Petrozza et al. found a 65% success rate of IVF among women with congenital absence of vagina and uterus.[26] None of the female births were noted to have congenital absence of uterus and vagina. To this day, there has been no study showing the hereditary nature of MRKH syndrome.

CONCLUSION

MRKH syndrome is a rare anomaly seen among females presenting with primary amenorrhea and normal secondary sexual characteristics. Imaging of the pelvis is vital to confirm uterine or vaginal agenesis. Psychological management is of utmost importance as the adolescent faces the challenges of infertility and acceptance of this condition. Surgical and nonsurgical options to create a neovagina are treatment options. In-vitro fertilization and surrogacy are offered to women who wish to bear children.

This report is a case of a 15 year-old female presenting with cyclic hypogastric pain. She had normal secondary sexual characteristics and absent vaginal canal. Ultrasound and MRI showed a rudimentary uterus and absent upper vagina with intact ovaries. Karyotyping showed 46, XX, confirming that the patient is a female. Analgesics were given for abdominal pain. Regular counseling is provided by an Adolescent specialist. The best approach in treatment is taken into consideration towards the patient's transitioning to adulthood.

APPENDIX A

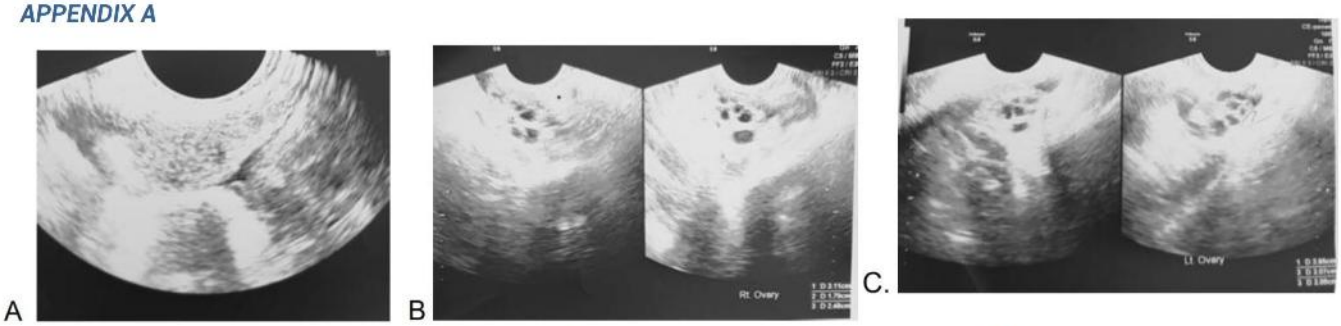

Figure 1. Transrectal ultrasound images. A: Uterus. B: Right ovary. C: Left ovary.

Uterus: 1.93 x 1.50 x 1.16 cm, anteverted
Endometrium: thin, 0.29 cm, hyperechoic
Right ovary: 3.11 x 2.48 x 1.79 cm
Left ovary: 2.85 x 2.09 x 2.07 cm
Cervix: 0.79 x 1.02 x 0.71 cm
No free fluid in the cul de sac

Impression:
Prepubertal anteverted uterus
Thin endometrium
Normal both ovaries

APPENDIX B

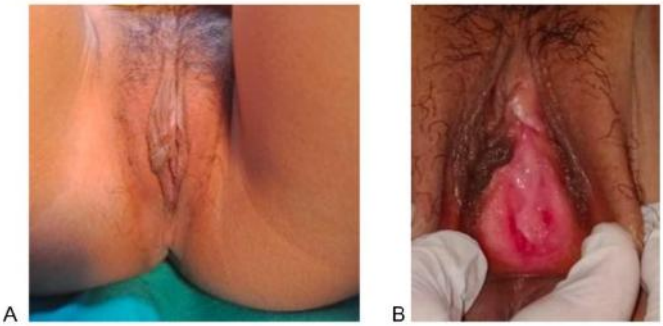

Figure 2. Gynecologic examination. A: External genitalia. B: Vaginal opening demonstrating a blind vagina

APPENDIX C

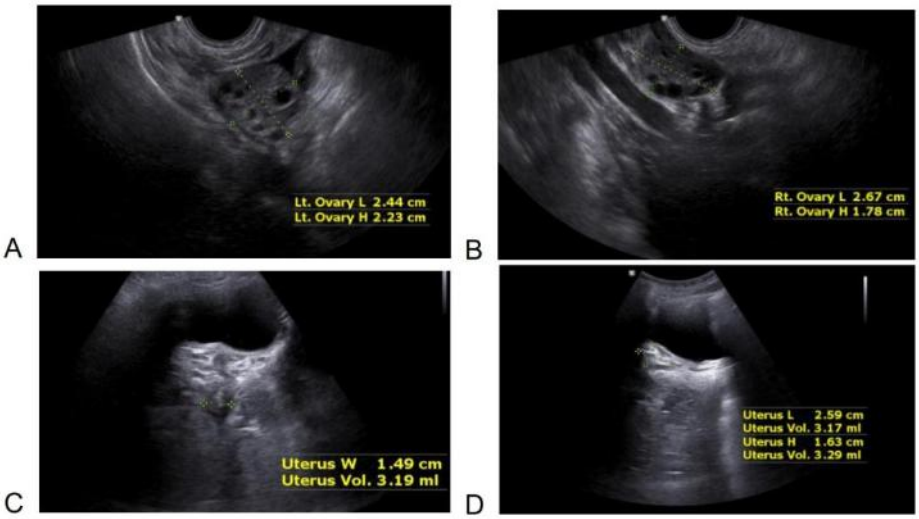

Figure 3. Transrectal ultrasound images. A: Left ovary. B: Right Ovary. C & D: Uterus.

Prepubertal uterus
Multicystic both ovaries
No adnexal masses seen
No heatometria
No free fluid in the cul-de-sac

APPENDIX D

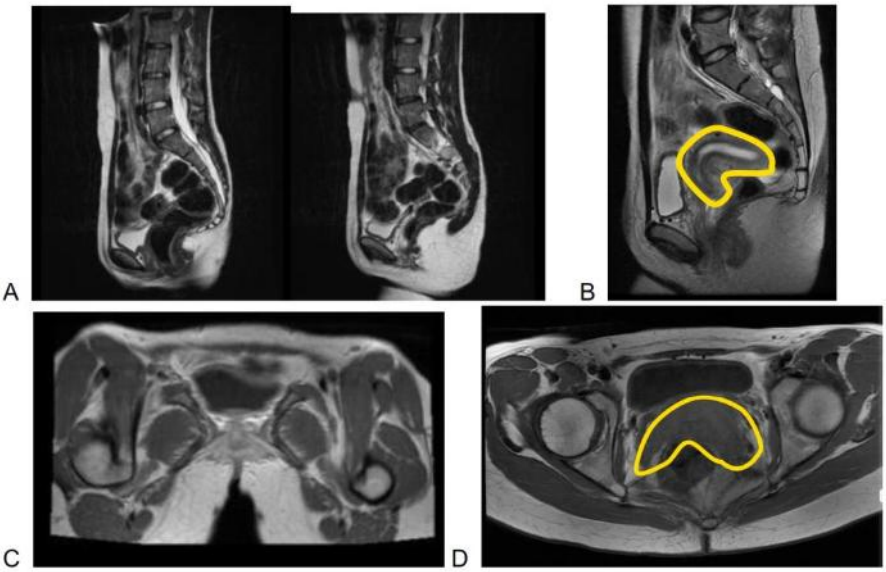

Figure 4. Pelvic MRI plain and contrast. A: Patient, T2-weighted sagittal view. B: Normal, T2-weighted sagittal view demonstrating the presence of a uterus. C: Patient, T1-weighted axial view. D: Normal, T1-weighted axial view demonstrating the presence of a uterus.

Uterus: no normal-looking uterus or cervix visualized. No pelvic masses noted.
Ovaries: multiple small cysts are noted in the right (2.4 x 1.3 cm) and left (2.5 x 1.9 cm) ovaries. No adnexal masses noted.
Urinary bladder: unremarkable.
Bowels: visualized bowels are unremarkable.
No other remarkable findings.

Impression:
No normal-looking uterus or cervix, consider agenesis
Multicystic ovaries, bilateral
No gross pelvic masses

APPENDIX E

Metaphase Counted:	15	**Banding Technique:**	G-Banding	**Number of Cultures:**	2
Metaphase Scanned:	30	**Band Resolution:**	≥ 450		
Metaphase Analyzed:	5	**Additional Method:**			
Metaphase Karyotyped:	3				

ISCN RESULT:	**46,XX** **Normal Female Karyotype**

CASE COMMENTS:

Chromosome analysis revealed a NORMAL female chromosome complement in all 50 cells examined. There was no evidence of a chromosome abnormality within the limits of current technology.

With a total of 50 metaphase cells examined, this should exclude mosaicism of greater than 6% at a 95% confidence interval (Am J Hum Genet 29:94-97, 1977) in this tissue.

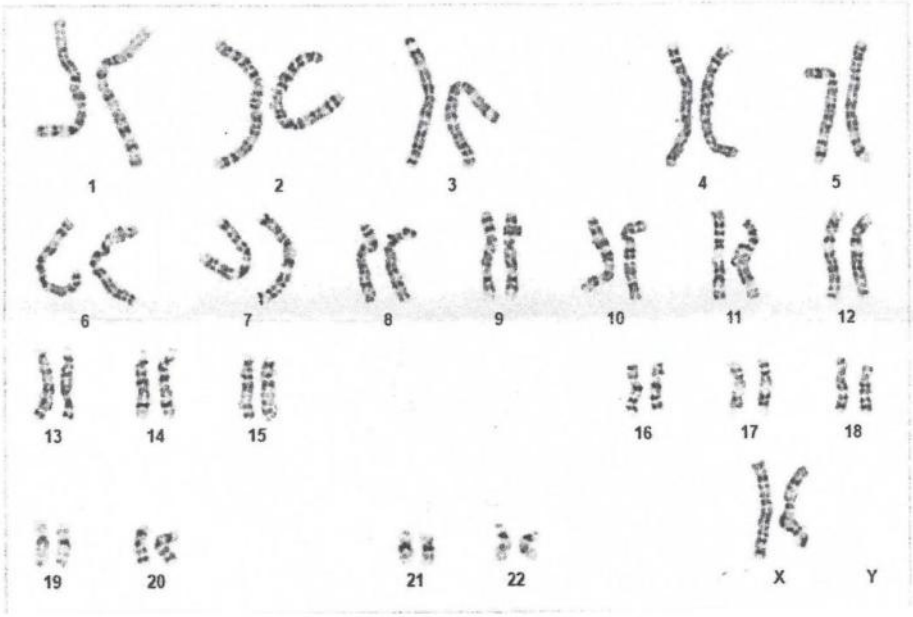

Figure 5. Karyotyping of the patient showing 46,XX, normal female karyotype.

Disseminated Zoster in an Immunocompromised*

Claudine Joy M. Ramos, MD[1]

ABSTRACT

In an immunocompromised patient such as HIV infection, disseminated herpes zoster is a common cutaneous manifestation. It is very important to have clinical suspicion of HIV, whenever a patient presents with cutaneous manifestation of HIV. This is a case of a 32 year old male who came in at for consult at our institution with a chief complaint of fluid filled bumps which started on the left abdominal area progressing to the trunk, upper and lower extremities with associated pricking pain. Patient was diagnosed with disseminated zoster and was given acyclovir with noted complete resolution of lesions. Laboratory tests were requested which revealed that the patient also had concomitant HIV and Hepatitis B. Patient was referred to the Center for Tropical and Travel Medicine for proper management.

Keywords: Disseminated zoster, HIV, Hepatitis B, acyclovir

INTRODUCTION

The Philippines has been ranked as the country with the fastest growing number of HIV cases in the world and in January, 2019, there are 1,249 newly confirmed HIV-positive individuals.[1] Disseminated zoster is one of the most common cutaneous manifestations of HIV in 25-50%, which, in advanced HIV disease, may present atypically with scattered vesicles in the absence of dermatomal lesions.[2] Early and prompt recognition of the cutaneous manifestations of HIV is very important to be able to start treatment.

CASE REPORT

This is a case of a 32 year old Filipino male, single from Makati who came in for consult last March 23, 2018 at our institution with a chief complaint of fluid filled bumps all over the body. History started 3 weeks prior to consult, patient was noted to have pain on the left abdominal area, pricking even with light touch, nonradiating, persistent and graded as 8/10. No fever, rashes, diarrhea, constipation or dysuria noted. No medications were applied or taken and no consult was done. 2 weeks prior to consult, patient noted fluid filled bumps on the left abdominal area, still with the same quality of pain. 1 week prior to consult, patient noted progression of the fluid filled bumps to the face, trunk, upper and lower extremities. Pain on the left abdominal area was noted to increase to 10/10. Persistence prompted consult at the Emergency room was diagnosed with herpes zoster with secondary infection. Patient was then referred to our department.

For the review of systems, patient was noted to have no fever, malaise, chills and vision loss or changes. No noted shortness of breath, dyspnea, chest pain or discomfort.

Patient was previously diagnosed with pulmonary tuberculosis in 2012 and treated with anti-Koch's medications for 6 months with normal chest radiography findings after treatment. Patient previously had cleft lip and palate repair. No medications taken, no allergies nor blood transfusion done. No similar lesions were seen with family members.

Sexual history revealed that the patient had his first coitus when he was 25 years old with more than 30 partners, with preference for both male and

*3rd Place, 2020 Philippine Medical Association Case Report Presentation, September 7, 2020

[1]Resident, Quirino Memorial Medical Center, Quezon City

female. Patient practices both anal and oral sexual intercourse with no use of protection such as condom. His last sexual encounter was on January, 2018. Patient was also diagnosed with anal fissure secondary to trauma. Patient works as a teacher in secondary education, is a non smoker and non-alcoholic beverage drinker and denies illicit drug use.

Physical examination findings revealed that the patient was awake, conscious, oriented to time place and person. Other physical examination was unremarkable except for the cutaneous manifestation with generalized involvement, lesions consist of multiple, well-defined, erythematous to hyperpigmented grouped vesicles with erythematous base, some with hemorrhagic crusts and erosions and some coalescing into plaques in a dermatomal distribution as seen in Figures 1-6.

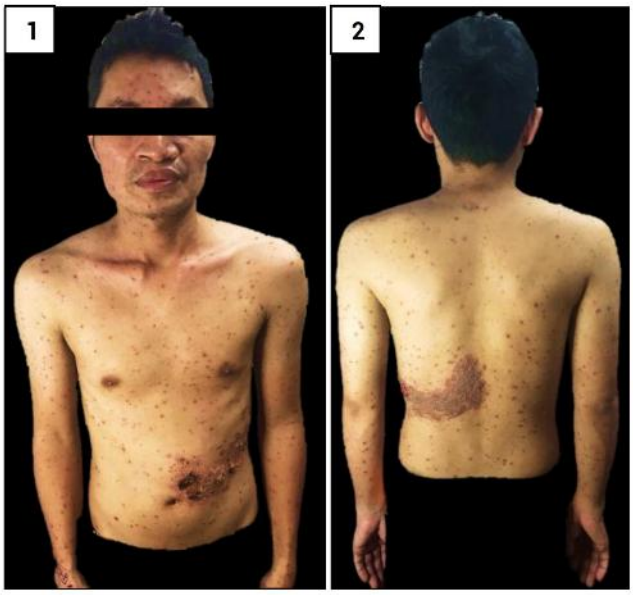

Figures 1-6. Generalized involvement, lesions consist of multiple, well-defined, erythematous to hyperpigmented grouped vesicles with erythematous base, some with hemorrhagic crusts and erosions and some coalescing into plaques in a dermatomal distribution

Gram stain and Mycologic examination using potassium hydroxide was done with negative results. Tzanck smear was also done which revealed the presence of multinucleated giant cells as seen in Figure 7.

Figure 7. Tzank smear: Multinucleated giant cells are present (white arrows)

Patient was advised. Patient was asked to do NSS compress to the affected areas for 15 mins 3x day. Medications given were Acyclovir, 800mg/tab 1 tab 5x a day and co-amoxiclav 625mg/tab, 1 tab 3x a day for 7 days. Patient was advised to refrain from sexual intercourse during the duration of management. Also, the individuals who had contact with the patient were asked to follow up at our institution, however, the patient had lost contact with those individuals. Patient was also referred to Ophthalmology department for evaluation of Herpes zoster ophthalmicus. Patient was asked to follow up after 1 week.

Diagnostic tests requested were CBC, chest radiography, RPE, Hepatitis B surface antigen and HIV screening with the following results (Tables 1-3).

Table 1. CBC results

	March 22, 2018	April 5, 2018	Reference Range
Hemoglobin	15.3	11.8	14 – 18 g/dL
Hematocrit	0.47	0.37	0.40 – 0.54
WBC count	**11.4**	7.4	4 – 11 x 109
RBC count	5.5	**4.3**	5 – 6.4 x 109
Platelet Count	330	410	150 – 450 x 109
Segmenters	70	56	50 – 70%
Lymphocyte	16	28	20 – 40%
Monocyte	**14**	**11**	2 – 5%
Eosinophil	0	**5**	2 – 4%

Table 1. Clinical Chemistry and Chest Xray-PA

	RESULT	REFERENCE RANGE
SGOT	35	5 – 35 U/L
SGPT	22	0 – 55 U/L
BUN	3.7	3.2 – 7.4 mmol/L
Creatinine	69	64 – 104 umol/L
Na	143	136 – 145 mmol/L
K	3.9	3.5 – 5.1 mmol/L
Chest Xray-PA	No significant findings	

Table 3: HIV, RPR and HbsAg Results

TEST	RESULTS
HbsAg	**Reactive**
RPR	Non-reactive
HIV test	**Positive**

Since we requested HIV screening for the patient, in accordance with Administrative order for the Policies and Guidelines for the conduct of HIV Testing Services in Health Facilities.[3] It is composed of different components. First is confidentiality in which the confidentiality of all data gathered from the patient shall be emphasized. Next, information. The HIV counselor shall provide the following information to the patient such as HIV and relationship with patient's current health condition, benefit of knowing one's HIV status and the flow of HIV test procedures. The patient shall be given the chance to express any other concern or needs in relation to HIV and test procedures.

HIV counselor shall review or validate the given information and patient is asked to sign the informed consent.

Since the patient is positive for HIV, patient underwent post-HIV test counseling. Confirmation test was done using the same blood sample by rapid HIV diagnostic algorithm. If the patient is negative for the confirmatory test, results are verified and patient is given a copy of the result. On the other hand, if the patient is positive, results are verified. Post-test counseling is done to ensure that the patient wound undergo treatment and follow up religiously. Patient underwent assessment for risk for suicide, self-harm or violence to others. Patient was also counseled on immediate support, risk reduction, protection such as condoms, disclosure to family and partners and to start antiretroviral treatment. In our case, the patient is referred to the Center for Tropical and Travel Medicine where counseling and CD4+ T cell count monitoring is done every 3 months. Patient was given a combination of Efavirenz, Lamivudine and Tenofovir once at bedtime with no reported rashes, fever or dyspnea after 1 month treatment. These were the CD4+ T cell counts before and 3 months after treatment (Table 4).

Table 4. CD4+ T cell counts before and 3 months after treatment

JUNE 6, 2018	SEPTEMBER 20, 2018
125 cells/mm^3	120 cells/mm^3

Patient came in for follow up at our department 4 months after the first consult with noted complete resolution of lesions as shown in Figures 8-13

Figures 8-13. Same patient 4 months after first consult. Note complete resolution of lesions.

DISCUSSION

Varicella (chickenpox) and herpes zoster (shingles) are distinct clinical entities caused by a single member of the herpesvirus family, varicella-zoster virus (VZV) (Friedman et. al., 2003). During primary infection of varicella (chickenpox), the varicella zoster virus (VZV) establishes latency in the dorsal root and cranial nerve ganglia. When the virus is reactivated, patients presents with herpes zoster infection or "shingles" and its spread from single ganglion to corresponding dermatome and neural tissue of the same segment. The lifetime risk of having herpes zoster infection in a person is 15% to 20%, with most cases occurring in the elderly and immunocompromised populations. Other possible risk factors for herpes zoster include physical trauma at the involved dermatome, psychological stress, and white race. Lesions are mostly distributed in the thoracic dermatomes (40%–50% of cases), followed by cranial nerve (20%–25%), cervical (15%–20%), lumbar (15%), and sacral (5%) dermatomes. Lesions starts as an erythematous macules and papules followed by the appearance of vesicles with noted pain then appearance of pustules and crusts which may last for 2 to 3 weeks. Although the rash is important, pain is the cardinal problem posed by herpes zoster, especially in the elderly. Most patients experience dermatomal pain or discomfort during the acute phase that ranges from mild to severe. Patients describe their pain or discomfort as burning, deep aching, tingling, itching, or stabbing. Patients compared the severity of herpes zoster pain to angina and kidney stones for prodromal; labor and post surgical pain for acute pain and arthritis and arthritis and fibromyalgia for chronic post herpetic neuralgia.[2]

Our patient presented with disseminated type of herpes zoster which is mostly seen in the elderly and patients with immunocompromised conditions such as human immunodeficiency virus infection, acquired immunodeficiency syndrome (AIDS), hematologic malignancies, organ transplants (especially bone marrow transplant), and immune-mediated diseases. Disseminated zoster means that there are at least 20 lesions outside the affected dermatome. In patients with concomitant infection with HIV, there is increased

severity of cutaneous lesions and the disease course may be prolonged. Herpes zoster is considered as an "opportunistic infection" in patients infected with HIV and often occurs as the first sign of immunodeficiency. The primary target organ for patients with disseminated herpes zoster with HIV co-infection is the CNS which may lead to neurologic syndromes such as CNS vasculitis, multifocal leukoencephalitis, ventriculitis, myelitis and myeloradiculitis, optic neuritis, cranial nerve palsies and focal brain-stem lesions, and aseptic meningitis.[4]

Dermatologic manifestations are very important indicators for the level of immunodeficiency of HIV patients as seen in Table 5.[2] In our case, disseminated zoster is seen in HIV patients with CD4+ T cell counts between 250-500/μL. So the clinical suspicion of immunocompromised state when faced with these dermatologic manifestations is very important.

Table 5. Correlation of Mucocutaneous Manifestations of Human Immunodeficiency Virus Infection with CD4 T Cell Counts

CD4 T CELL COUNT > 500/μL	500/μL > CD4 T CELL COUNT > 250/μL	CD4 T CELL COUNT < 200/μL
Acute retroviral syndrome Herpes zoster infection (nondisseminated) Seborrheic dermatitis	Dermatophyte infections, recurrent or persistent Oral candidiasis Oral hairy leukoplakia **Herpes zoster infection, disseminated**	Bacillary angiomatosis Hyperkeratotic scabies Cutaneous miliary tuberculosis Eosinophilic folliculitis Herpes simplex virus infection (>1 month's duration) Idiopathic pruritus Invasive fungal infections Kaposi's sarcoma Molluscum contagiosum, large facial lesions Papular pruritic eruption of HIV

In the Philippines, there is an increasing number of newly diagnosed cases of HIV. In a cross-sectional analytical hospital-based study by Abdalla et. al.[5], conducted at Khartoum Dermatology Hospital in Khartoum city, wherein they determined the HIV seroprevalence in patients with herpes zoster infection and to identify the factor that may affect its prevalence. Patients who came in with a diagnosis of herpes zoster were examined and blood samples were tested for presence of antibodies against HIV using ELISA technique and confirmed by Western blot. A total of 40 patients were screened and 6 (15%) were seropositive for HIV. Of all HIV positive patients, 5 (83%) were in the age group 25- 45 years and most of them were females residing in urban areas (83%). The head was the most affected area (67%) and only 2 cases (33%) had multi dermatomal involvement.

Aside from disseminated zoster, patients with HIV may have co-infection with Hepatitis B since both of them are sexually transmitted diseases. Since risk factors for acquisition are the same for both disease entities, coinfections are common globally. Among patients with HIV, the leading cause of end stage liver disease worldwide is chronic Hepatitis B with a prevalence ranging from 5-20% in various studies of HIV-infected subjects.[6]

Infection with both Hepatitis B and HIV compromise the benefits of efficient antiretroviral drugs by increasing the morbidity and mortality in patients infected with HIV. Both viruses are blood-borne and because of their shared transmission, people at risk for HIV infection are also at risk for HBV infection. Also, co-infection alters the natural history of the disease in which the progression to chronic hepatitis is accelerated, resulting in more complications in the patient's condition which may lead to deterioration of the many vital organs especially, the liver with noted increase in the levels of liver enzymes like alanine aminotransferase in the blood stream.[6]

Immediately after diagnosis of disseminated herpes zoster and HIV co-infection, prompt antiviral therapy with oral valacyclovir, famciclovir, or acyclovir for 7 to 10 days, although

longer durations are recommended if lesions resolve slowly. Because of their improved pharmacokinetic properties and simplified dosing schedule, valacyclovir or famciclovir are preferred. For extensive cutaneous lesions and if visceral organs are involved and suspected, IV acyclovir should be initiated and continued until clinical improvement is evident.[7]

In patients with HIV and Hepatitis B co-infection, the principal goal of management is to stop or decrease the progression of liver disease and prevent cirrhosis and hepatocellular carcinoma. Control of HIV infection is the usual priority when treating HIV-HBV–coinfected patients. In treating these patients, the needs of individual patients should depend on the clinical status of both HIV and HBV, and whether they will be treated concurrently, should always be kept in mind. Other considerations are need for combination antiretroviral therapy for HIV infection, the severity of liver disease, the likelihood of response, and potential adverse events. Indications for treatment of HIV and Hepatitis B co-infection include All HIV/HBV coinfected patients, regardless of CD4 count and HBV DNA level. HBV reactivation can occur during treatment of HCV infection in the absence of HBV-active drugs; therefore, all HBV patients who will be treated for HCV should be on HBV-active ART at the time of HCV treatment initiation. Tenofovir disoproxil fumarate (TDF) 300 mg + Emtricitabine (FTC) 200 mg OR Lamivudine (3TC) 300 mg OR Tenofovir alafenamide (TAF) 10 or 25 mg + Emtricitabine (FTC) 200 mg is the preferred treatment regimen for HIV and Hepatitis B co-infections.[6]

CONCLUSION

Cutaneous manifestations may be the early and the only sign of HIV infection. The early recognition and management in HIV patients with co-infections of Hepatitis B and Herpes zoster is very important.

REFERENCES

1. HIV/AIDS and ART Registry of the Philippines: January 2019. Epidemiology Bureau, Department of Health (2019)
2. GOLDSMITH, L. A. Atopic Dermatitis. Fitzpatrick's Dermatology in General Medicine Eighth Edition. McGraw Hills Companies, Inc. 2012
3. Administrative Order 2017-0019: Policies and Guidelines for the conduct of HIV Testing Services in Health Facilities. Department of Health. Philippines
4. Bolognia, Jean L., MD. Dermatology 3rd Edition. 2012. Elsevier Limited.
5. Abdalla AO, Elkhidir IM, Bashir AA (2015) HIV Seropositivity among Patients Presenting with Herpes Zoster Infection. J AIDS Clin Res 6:413. doi: 10.4172/2155-6113.1000413
6. Marceline, Djuidje Ngounoue, Ambassa Axel Cyriaque, Guiateu Tamo Ida Marlene and Moundipa Fewou Paul (2017). Human immunodeficiency virus and hepatitis B virus (HIV/HBV) co-infection in people living with HIV/AIDs identified in Yaoundé Central Hospital, Cameroon: Seroprevalence and impact on the disease progression. Journal of AIDS and HIV Research Panel on Opportunistic Infections in HIV-Infected Adults and Adolescents. Guidelines for the prevention and treatment of opportunistic infections in HIV-infected adults and adolescents: recommendations from the Centers for Disease Control and Prevention, the National Institutes of Health, and the HIV Medicine Association of the Infectious Diseases Society of America. Available at http://aidsinfo.nih.gov/contentfiles/lvguidelines/adult_oi.pdf. Accessed (September 15, 2018)
7. SYLVA, PLK DE, KM Shah and Yogesh Chander. HIV Infection In Herpes Zoster (2017). https://www.ncbi.nlm.nih.gov/pmc/articles/PMC5531581/

CT Scan Guided Interscalene Brachial Plexus Neurolysisusing 95% Alcoholina Patient with Neurogenic Thoracic Outlet Syndrome: A Case Report*

Dean D. Roscom, MD[1]

ABSTRACT

A number of patients with thoracic outlet syndrome experience intractable pain unresponsive to pharmacologic treatment. In this case, a brachial plexus neurolysis was performed to address the patient's pain secondary to an enlarging left supraclavicular node. Guided under CT scan, 3 ml of 95% alcohol was injected in between the anterior and middle scalene muscles onto the trunks of the left brachial plexus, affording immediate pain relief. Particular concerns of motor blockade, phrenic nerve palsy, stellate ganglion blockade, and bleeding did not occur. Therefore, brachial plexus neurolysis can be safely done at a lower volume, without the above debilitating complications. It can be an option in relieving intractable upper extremity pain.

Keywords: Alcohol Neurolysis, Brachial Plexus, Thoracic Outlet Syndrome

INTRODUCTION

Neurogenic thoracic outlet syndrome may cause pain in the neck, shoulder and arms secondary to compression of the neurovascular structures1. In most cases, depending on the etiology, it may become severe rendering conventional analgesic regimens ineffective. In such cases, more invasive options may be offered. Chemical neurolysis is a commonly used tool by interventional pain specialists for severe intractable pain2. Although popular and common, literature on its application on the brachial plexus is scant. Only a few successful documented cases have been published.

In this case report, we present a successful chemical neurolysis of the brachial plexus via interscalene approach in a patient with an enlarging left supraclavicular lymph node.

PRESENTING CONCERNS

This is a 51-year-old female diagnosed with Stage IVA (T2A, N3, M1) Squamous Cell Carcinoma of the lungs last November 2019. The patient received 6 cycles of chemotherapy, 6 cycles of immunotherapy, underwent left partial mastectomy due to a benign mass, and is a known hypertensive and asthmatic. Patient was first seen by a pain specialist 2 months prior to admission due to constant pain of the left shoulder and upper extremity radiating to the back and left anterior chest wall, 4/10 on numeric pain scale (NRS). This resulted to difficulty in performing activities of daily living (ADLs).

CLINICAL FEATURES

Previous admission CT scan revealed a 2.92 x 2.58 cm mass at the left supraclavicular area as well as pulmonary and mediastinal nodes. The following pain medications were started: (1) Oxycodone 10mg tablet every 6 hours, (2) Oxycodone 5 mg capsule as needed every 4 hours for severe pain, (3) Paracetamol 900 mg intravenous every 8 hours, and (4) Pregabalin 50mg tablet once daily reducing pain score to 2/10. Patient was discharged improved with same opioid and gabapentinoid agents as home medications. Outpatient Radiotherapy and immunotherapy were then carried out. In the interim, there was progressive enlargement of the mass associated with increasing severity of pain. An ultrasound guided brachial plexus block using a local anesthetic was attempted by a regionalist but was aborted due to non visualization of the targeted structures secondary to a distorted anatomy. Instead, an ultrasound guided left superficial cervical plexus block using Ropivacaine 0.2% 5ml was performed which afforded a 3-hour relief. Patient was referred to interventional pain medicine for evaluation wherein an option to do neurolysis was discussed.

*1st Place, 2020 Philippine Society of Anesthesiologists Inc. Interesting Case Presentation

[1]From Davao Doctors Hospital

DIAGNOSTIC APPROACHES

Patient was readmitted due to radiation induced gastritis. Physical exam showed a swelling and erythema of the left supraclavicular area and a3 x 2 cm, smooth, movable and tender mass. Pain then was continuous 8-9/10 and unrelieved by current oral analgesics. Repeat CT Scan revealed an increase in size of the mass to 3.8 x 4.5 cm. Diagnostic exam revealed multiple electrolyte imbalances secondary to vomiting and poor intake. ECOG Performance Status was 3/5 or symptomatic with less than 50% in bed during the day and Karnofsky score of 30-40.

THERAPEUTIC APPOACHES

Further up titration of current pain medications to Oxycodone 80 mg tablet once daily with rescue dose of Oxycodone 10mg capsule every 1-hour interval did not improve pain control. Hence was shifted to Oxycodone 40mg with Naloxone 20mg tablet every 8 hours with rescue doses of Oxycodone 10mg intravenous. Pregabalin 50 mg was increased to every 8 hours, Ketamine at 10 mg/hour IV drip and an intravenous NSAID enantiomer Dexketoprofen 50 mg every 8 hours were started. Pain control improved to 3/10 for 3 days until patient developed orthopnea, dyspnea, visual hallucinations and hypotension. Round the clock nebulization and an antiarrhythmic drip were started by pulmonology and cardiology services respectively. With patient on NPO, opioid rotation was started by pain medicine service with IV Fentanyl drip at 25mcg/hour with rescue doses of Fentanyl 50 mcg at 1-hour interval as needed. Optimal pain relief was attained at 150 mcg/hour hence after 24 hours, was shifted to a transdermal delivery system at the said dose every 72 hours. With the primary objective to reduce opioid dose, minimize toxicity and optimize pain control, brachial plexus neurolysis was carried out.

On the 4th hospital day, the patient was placed comfortably in a supine position with the head slightly turned to the right. A pre-procedural CT scan was taken to locate the brachial plexus and and confirm tumor location. Lidocaine 2% 3 mL was used to infiltrate the skin using a gauge 25 hypodermic needle and later used as a marker. A 9 cm gauge 20 Quincke needle was inserted at the level of C6-C7, at a 50-degree angle, traversing the supraclavicular mass, until approximately 6 cm from the skin. Contrast medium Iopamidol 612mg/ml 1:1 dilution with PNSS at 1.5 ml was injected and established the correct placement of the spinal needle. 3 ml of 95% alcoholl was slowly administered. Patient complained of severe pain during the injection of alcohol.

The patient tolerated the procedure very well without dyspnea, bleeding, paralysis of the left upper extremity or Horner's Syndrome. There was immediate pain relief from 8/10 to 2/10 and further drop to 1/10 a few hours after the procedure. With significant pain relief, patient was able to perform ADls such as feeding, change of clothing and was able to sleep without interruptions. Fentanyl patch and Gabapentinoid doses were reduced by 50%, ketamine intravenous drip down to 2mg/hour from 10mg/hour and NSAID subsequently discontinued. Unfortunately, after 2 weeks, patient succumbed to complications of pneumonia and sepsis.

DISCUSSION

Neurogenic thoracic outlet syndrome is the most common form of thoracic outlet syndrome. Its etiologies include compression of the neurovascular structures secondary to scalene hypertrophy, enlarging mass in the area or the presence of a cervical rib. This could result to neck, shoulder and arm pain1. In this case, compression of the brachial plexus resulted to excruciating pain, unresponsive to the WHO's analgesic ladder. Considering the location of the pain, an interscalene brachial plexus neurolysis was identified as the most appropriate modality. However, with the very limited literature about this procedure, there is no consensus with regard to the volume of neurolytic agent to be injected. An inappropriate volume could spread to adjacent structures such as the phrenic nerve causing palsy or a motor block. A case report of a successful brachial plexus neurolysis for

cancer pain secondary to a right supraclavicular mass using 11 ml of 90% dehydrated ethanol has been reported. However, undesired motor block was observed after the procedure[2]. Another successful report of infraclavicular approach brachial plexus neurolysis using 5% Phenol has been documented[3]. Patient amenable for brachial plexus neurolysis have to be carefully selected. Indications include severe intractable pain, advanced malignancies, terminally ill, and well localized pain. Procedural adverse events include infection, metastatic cancer spread to the region and bleeding secondary to chemotherapy induced thrombocytopenia. In most instances, a brachial plexus block is done prior to a neurolysis[4]. However, its was not done in this patient as the volume of local anesthetic agent could dilute the neurolytic agent or cause further spread to adjacent structures.

The first problem encountered in this case was the volume of neurolytic agent to be used that would be sufficient enough to cause neurolysis and safe enough not to cause the untoward side effects considering that the anatomy was distorted from the enlarging mass. This would mean a smaller working area for the neurolytic agent. The problem was resolved by injecting and documenting the degree of spread of a specific volume of contrast medium, identified at 3 ml. This entails that at such volume, its degree of spread would most likely cover the area of the contrast medium. Another problem encountered was gaining access to the brachial plexus. The mass was obscuring an interscalene approach to the brachial plexus thus; the decision of traversing the mass was done.

CONCLUSION

The patient presented in this case gives us an insight into other alternatives other than pharmacologic treatment that would improve the quality of life of these patients who are mostly in the terminal stages of their disease. Specifically, this case is an anecdote that at such volume, desired sensory block of brachial plexus with the same neurolytic agents could be achieved.

REFERENCES

1. Christ P. "New Perspectives on Neurogenic Outlet Syndrome". Practical Pain Management. Volume 14. Issue #8(2015): p 1-3.
2. Loh T., Patel S., Mirchandani A., Eckmann M. (2018) "Brachial Plexus Chemical Neurolysis with Ethanol for Cancer Pain". Case Reports in Medicine 2018, 1-3. http://doi.org/10.1155/2018/8628645
3. Nader A, Kendall MC. (2015) "Selective infraclavicular brachial plexus phenol injection for the relief of cancer pain," Anesthesiology, vol. 122, no. 5, p. 1153, 2015.
4. Cousins M, Carr D, Horlocker T, Bridenbaugh P, editors. 4th ed. Philadephia: Lippincott; 2009. Neural Blockade In Clinical Anesthesia and Pain Medicine. pp 1118-1123
5. Diwan S, Staats P, editors. Pennsylvania: McGraw-Hill; 2015. Atlas of Pain Medicine Procedures.
6. Koyyalagunta MP, Engle JY, Feng L, Movy DM, "The effectiveness of alcohol versus phenol based splanchnic nerve neurolysis for the treatment of intra-abdominal cancer pain," Pain Physician, vol. 19, pp. 281-292, 2016.

Fig. 1 – Supraclavicular Mass

Fig. 2 – Procedural CT Scan. Yellow arrow: Tip of needle with dye. Red arrows: Mass

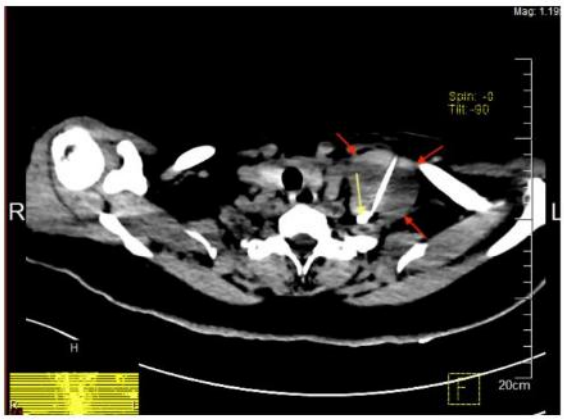

Fig. 3- CT Guided Brachial Plexus Neurolysis

Two Wrongs Make a Right: A Case Report on the Anesthetic Management of a Pediatric Patient with Congenitally Corrected Transposition of Great Arteries*

Karla Adrielle N. Villasin, MD[1]
Mariza M. Yumang, MD, DPBA[1]

ABSTRACT

Congenitally corrected transposition of the great arteries (ccTGA) or ventricular inversion, is a rare form of congenital heart disease (CHD) representing approximately 0.5% of all CHD. It is characterized by atrioventricular and ventriculoarterial discordance, in which the atria are connected to the opposite ventricle, and the ventricles are connected to the incorrect great artery. The defect is termed "corrected" because of the physiologic flow of blood through the body despite the malformation. ccTGA can be associated with other cardiac anomalies like ventricular septal defect (VSD), pulmonary outflow tract (LVOT) obstruction, tricuspid valve lesions, and coronary artery anomalies.

This paper aims to discuss the anesthetic management unique to patients with ccTGA in which the ultimate goal is to prevent hemodynamic instability that could potentially lead to cardiac failure. Here, we report the anesthetic management of a 6 year old child with ccTGA with mild tricuspid regurgitation who underwent plastic repair of cleft lip under general endotracheal tube anesthesia (inhalational). With use of balanced anesthesia to produce minimal to no cardiovascular effects, the operation concluded successfully.

Keywords: congenitally corrected transposition of great arteries, non-cardiac surgery

INTRODUCTION

Congenitally corrected transposition of the great arteries (ccTGA) is a rare defect described as atrioventricular discordance with ventriculoarterial discordance (double discordance). It occurs in approximately 0.5 to 1.4% of all congenital heart diseases[1].

In this anomaly, there is ventricular inversion and malposition of great vessels (Figure 1). The morphologic right atrium empties into an anatomic left ventricle across the mitral valve, which then contracts into the pulmonary trunk. The morphologic left atrium opens into an anatomic right ventricle across the tricuspid valve, which ejects into the aorta. The aorta is usually oriented in a leftward and anterior position with respect to the pulmonary artery, thus accounting for nomenclature of L-transposition of the great arteries (L-TGA) in this lesion[2].

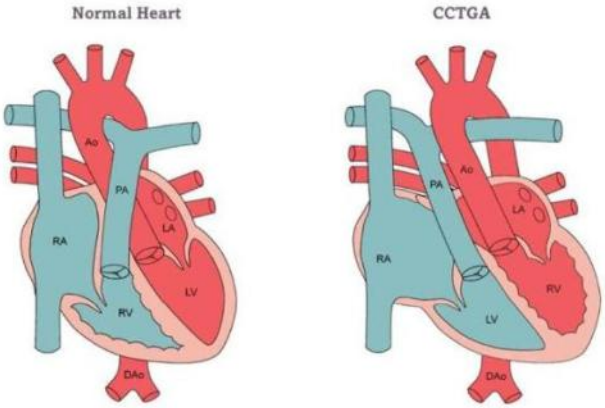

Figure 1. Congenitally Corrected Transposition of Great Arteries3

2nd Place, 2020 Philippine Society of Anesthesiologists Inc. Interesting Case Presentation
[1]*From Bataan General Hospital and Medical Center*

The anatomic right ventricle functions as the systemic pump in this lesion. Cyanosis is absent because the circulations are physiologically corrected. However, associated defects are frequently present and these include pulmonary outflow tract obstruction, an interventricular communication, and tricuspid valve (left-sided) abnormalities. If without associated abnormalities, ccTGA may go unnoticed until adolescence or adulthood. This pathology may remain undetected until onset of arrhythmias or syncope is seen which may be attributed to complete heart block or the effects of concomitant defects later in life. Issues that require long term surveillance in children with congenitally corrected transposition include right ventricle (RV) performance and tricuspid valve competency[2]. The inherent vulnerability of RV to failure is due to worsening atrioventricular valve (AV) regurgitation and ischemia because there is only a single main artery supply unlike the morphological left ventricle.

This is a case report of the perioperative anesthetic management of a congenitally corrected TGA who is to undergo cleft lip repair under general anesthesia.

CASE SUMMARY

A 6-year-old female, Filipino, presented to the outpatient department for primary repair of cleft lip. No previous admissions or surgeries undergone. She has no history of seizures, asthma, nor pulmonary tuberculosis. She has no known allergies to food and drugs. Patient had complete childhood immunizations (Hepatitis B, Diphtheria, Tetanus, Polio, Hib, BCG).

Patient was born to a 30 year old GlP0 full term via normal spontaneous delivery with birth weight appropriate for gestational age. At birth, cleft lip, incomplete, right, was noted. There were no feto-maternal complications noted. The mother denies any illnesses during pregnancy. Newborn screening was unremarkable.

Patient is currently a kindergarten student, and active at school. Developmental history is at par with her age. There was no noted poor weight gain and feeding intolerance.

There was no noted familial diseases such as hypertension, diabetes, cancer, PTB. No family history of mental retardation, congenital anomalies nor growth problems.

On physical examination, blood pressure (BP) was 90/60 mmHg, heart rate (HR) was 89 beats per minute, respiratory rate (RR) was 19 breaths per minute, temperature was 36.5 deg C, and body weight was 21.3 kg. Cardiac examination showed adynamic precordium, with normal heart rate, S2>S1, and a grade 1 systolic murmur heard at the 5th left interspace midclavicular line. No peripheral cyanosis or clubbing of the fingers noted. Lung, abdominal and neurological examination was unremarkable.

Patient was then referred to Pediatric Cardiology service for which cardiopulmonary work-up was done. Chest radiograph was unremarkable. Electrocardiogram showed sinus rhythm with a normal PR interval and left axis deviation, while her 2D echo revealed ventricular inversion with associated mild tricuspid regurgitation. Results of other laboratory examinations, such as CBC with platelet count, prothrombin and partial thromboplastin time, electrolytes and kidney function tests, were within normal limits. Hence, patient was classified as American Society of Anesthesiologists (ASA) Class 2 for Ventricular Inversion. The anesthetic plan (GETA), risks, and possible complications were explained, understood and accepted by the patient. Informed consent for anesthesia was obtained from the mother. Patient was maintained on NPO as follows: Intravenous line (gauge 22) established prior to OR and venoclysis done with 5% dextrose in 0.3% sodium chloride at 62-63 cc/hr.

Patient was received in the operating room and standard monitors were attached. Vitals signs were: BP 100/70 mmHg, HR 120 bpm, RR 28 cpm and temperature of 36.5 degrees celsius. Preoxygenation with 100% oxygen via a tight fitting mask for 5 minutes was done.

Induction was started with IV midazolam 2mg (0.1mg/kg) and ketamine 35mg (1.5mg/kg), sevoflurane 3% vol, neuromuscular blockade was

achieved with intubating dose of atracurium 10mg (0.5 mg/kg) IV. Two pumps of lidocaine spray 1.0% (1mg/kg) was also given topically. The patient was then intubated under direct laryngoscopy using MAC3 with endotracheal tube (ETT) 5.0mm ID, secured at level 15cm, and cuff inflated with 1mL of air, taped and secured. Endotracheal placement was confirmed using 5 point auscultation, and capnography. Vital signs were as follows: BP 100/70 mmHg, HR 111bpm, RR 22 cpm, temperature of 36.5 C, end tidal carbon dioxide (EtCO2) of 33. Preventive analgesia with Paracetamol 300 mg (15mg/kg) IV was given while patient was being prepped prior to surgery.

Mechanical ventilation was set at volume assist control. Respiratory frequency was adjusted to achieve a tidal volume (VT) of 140 (7cc/kg) and an intraoperative EtCO2 35–45 mmHg. Sevoflurane was maintained at 2.5% volume in 100% oxygen. Vital signs remained stable all throughout the procedure (BP 90-102/60-68 mmHg, HR 102-106 bpm, SpO2 99-100%), and the surgery lasted for 45 minutes. There was minimal blood loss of about 30 mL, with total of 200 mL crystalloid given and urine output of 30 mL. The patient was extubated awake and follows commands. Suctioning was done with minimal secretions. Vital signs were: BP 100/60 mmHg, HR 110 bpm, RR 23 cpm and temperature of 36.4 C. Patient was then transferred to the post-anesthesia care unit (PACU). For post-operative pain, paracetamol 300mg (15mg/kg) TIV was continued every 8 hours and started with ketorolac 10 mg every 8 hours for 24 hours. She was then shifted to oral paracetamol 300mg every 8 hours for the next 3 days. Her postoperative course was uneventful and was discharged after 1 day. On follow up, 1 week post-operative, the patient had no complaints.

DISCUSSION

Any cardiac patient that is to undergo surgery is always a challenge to the anesthesiologist. These patients usually undergo a relatively long period of preoperative preparation. The most important factor in minimizing the problems of anesthesia itself is the skill and knowledge with which the anesthetic agents are chosen and administered. It consists of careful selection of preanesthetic medication, flawless technique, and use of minimal quantities of anesthetic agents and adjuncts.

The cardiac abnormalities present in the patient must first be taken into consideration.

The main complication of ccTGA affecting patients' function and life expectancy is systemic (morphologic right) ventricular dysfunction resulting from pressure and volume overload.4 The pressure overload occurs as the RV pumps blood against the high systemic pressures, while volume overload can be caused by tricuspid regurgitation and relative myocardial hypoperfusion (supplied with a single (right coronary) artery). The morphologically right ventricle is unable to sustain the demands of a systemic ventricle due to absent helical myocytic arrangement, typically seen in a normal left ventricle, which is important in twisting or torsion during systole5. Hence, any suppression of contractility may induce RV failure. In addition to these, there can also be conduction abnormalities. Every year, around 2% of patients with ccTGA acquire complete AV block and was said to be caused by the displacement of AV node and abnormal course of conduction tissue[6].

In our patient who has ventricular inversion with mild TR, the perioperative hemodynamic goal thus, is to maintain forward flow in the regurgitant valve, prevent arrhythmias and right ventricular dysfunction. To maintain forward systemic flow, the following must be achieved: 1) avoid bradycardia to decrease regurgitation, 2) avoid decrease in preload since low preload results in inadequate cardiac output, 3) contractility should be maintained or increased to decrease the morphologic RV volume. These were achieved by balanced anesthesia with sevoflurane, ketamine (1mg/kg) and atracurium (0.5mg/kg).

A popular drug used in induction is propofol. However for this case, since propofol is a cardio-depressant drug, ketamine was used instead. The advantage of ketamine over propofol is that it has cardio-stimulant properties which make it a useful drug for patients with impaired cardiac function7. It stimulates the cardiovascular system resulting in an increase in heart rate, blood pressure and increase in cardiac

output, mediated principally through the sympathetic nervous system. It has minimal effects on central respiratory drive and produces airway relaxation by acting on bronchial smooth muscles, thus resulting to increased pulmonary blood flow. The increase in pulmonary blood flow then leads to improved oxygenation[8]. All of which are beneficial to our patient.

Volatile anesthetics also have an impact on the cardiovascular system through its effects on the myocardium and on the systemic vascular resistance. Studies suggest that cardiac output during sevoflurane anesthesia, at clinically relevant concentrations, is not substantially decreased, but rather preserved. According to the authors, there is also no evidence for a relevant coronary steal phenomenon in patients given sevoflurane. Sevoflurane is said to act as a weak coronary vasodilator, with coronary blood flow maintained[9].

Despite the reported hemodynamic changes due to release of histamine after administering atracurium, several studies have used atracurium in patients with congenital heart disease [10,11]. Its use is still being recommended given that its dose is decreased[12].

Intraoperative hemodynamics is also an important issue the anesthesiologist must deal with. Hypotension is common post-induction and during maintenance of anesthesia. Hypotension can decrease coronary artery perfusion. In patients having noncardiac surgery, the occurrence of perioperative hypotension was associated with cardiovascular events regardless of the degree of coronary artery disease[13]. Having said, hypotension should be avoided. There are several factors contributing to intraoperative hypotension and preoperative dehydration is one of them. Preload and afterload can be preserved by simple adequate hydration and liquid replacement. Dopamine or vasoconstrictors are helpful in cases of volume depletion and shock[12]. In our case, these were not necessary since there was no volume deterioration. Moreover, since there was adequate diastolic function, liberal IV fluid administration can be done.

Effective pain control must be also achieved to reduce stress, adverse hemodynamics and hypercoagulable states. In our case, aside from preventive analgesia, a topical anesthesia was given prior incision.

CONCLUSION

Any cardiac patient to undergo non-cardiac surgery poses great challenges to the anesthesiologists. The key to success is a thorough evaluation and planning -- from preparation of patient preoperatively, to the use of balanced anesthesia with ketamine, sevoflurane and atracurium in maintenance of hemodynamic stability intraoperatively and finally to the use of multimodal analgesia postoperatively.

REFERENCES

1. Tandon A., Bose R., Yoon A. D., Schussler J. M. Isolated congenitally corrected transposition of the great arteries with dextroversion discovered incidentally in a patient with cocaine-induced acute myocardial infarction. Proceedings (Baylor University. Medical Center) 2016; 29(2): 171-173.
2. Ryan JF, Todres ID, Cote CJ, et al, eds. A Practice of Anesthesia for Infants and Children. Philadelphia, PA: WB Saunders; 2016.
3. Congenitally Corrected Transposition of the Great Arteries (CCTGA). (n.d.). Retrieved November 2, 2019, from achaheart.org/your-heart/health-information/cctga/.
4. Tawfik, Mohamed & Hafez, Helmi & Abdelkhalek, Mostafa & Allakkany, NasserSameh. (2015). Combined spinal-epidural anesthesia for cesarean section in a parturient with congenitally corrected transposition of the great arteries. Journal of Anesthesiology Clinical Pharmacology.
5. Wallis, G.A., Debich-Spicer, D. & Anderson, R.H. Congenitally corrected transposition. Orphanet J Rare Dis 6, 22 (2011) doi:10.1186/1750-1172-6-22
6. M. Kayrak, Z. Kaya, E. E. Gul et al., "Congenitally corrected transposition of great arteries with severe rhythm disturbances," Indian Pacing and Electrophysiology Journal, vol. 10, no. 4, pp. 179-183, 2010.

7. Mazzeffi M, Johnson K, Paciullo C. Ketamine in adult cardiac surgery and the cardiac surgery Intensive Care Unit: an evidence-based clinical review. Ann Card Anaesth. 2015;18(2):202-209.

8. Kurdi MS, Theerth KA, Deva RS. Ketamine: Current applications in anesthesia, pain, and critical care. Anesth Essays Res. 2014;8(3):283-290.

9. Brioni JD, Varughese S, Ahmed R, Bein B. A clinical review of inhalation anesthesia with sevoflurane: from early research to emerging topics. J Anesth. 2017;31(5):764-778.

10. Junghare, S. W., & Desurkar, V. (2017). Congenital heart diseases and anaesthesia. Indian journal of anaesthesia, 61(9), 744-752.

11. ST Verghese & RS Hannallah (2008) Anesthesia for non-cardiac surgery in children with congenital heart disease, Southern African Journal of Anaesthesia and Analgesia, 14:1, 84-86

12. Haryalchi K, Ghanaie MM, Arejan NH, Farhadytoli L. Management of anesthesia in a pregnant patient with an unmodified congenital heart disease. J Basic Clin Reprod Sci2014;3:58-61

13. Pavel S. Roshanov, Tej Sheth, Emmanuelle Duceppe, Vikas Tandon, Amal Bessissow, Matthew T. V. Chan, Craig Butler, Benjamin J. W. Chow, James S. Khan, P. J. Devereaux; Relationship between Perioperative Hypotension and Perioperative Cardiovascular Events in Patients with Coronary Artery Disease Undergoing Major Noncardiac Surgery. Anesthesiology 2019; 130(5):756-766.

APPENDIX

2D ECHOCARDIOGRAPHY

FINDINGS:

Normal abdominal situs

Apex at the left side of the chest

Atrioventricular discordance and ventriculoarterial discordance

Intact interatrial and interventricular septae

Apically displaced and septophilic atrioventricular valve is attached to the coarsely trabeculated left sided ventricle

Septophobic atrioventricular valve is attached to the finely trabeculated right sided ventricle

Non thickened and well coaptating atrioventricular and semilunar valves

Normal chamber sizes

Good right and left ventricular function

Tricuspid annular plane systolic excursion of 1.73cm

Tricuspid regurgitation, mild TR jet of 12mmHg

Normal color flow doppler across mitral and semilunar valves

Normal sized coronary arteries arising from two different ostia

Normal estimated pulmonary artery pressure by PAT, kindly correlate clinically

Left sided aortic arch

No coarctation of aorta

No patent ductus arteriosus

FINAL INTERPRETATION: Ventricular inversion

Anesthetic Management of a Pediatric Patient Diagnosed with Bilateral Hereditary Pheochromocytoma: A Case Report*

Miguel Angelo Poblete, MD[1]

ABSTRACT

Pheochromocytoma is a rare, catecholamine secreting tumor, accounting for 1% of pediatric hypertensive patients[1]. In children, pheochromocytoma is even more infrequent and are mostly bilateral[2]. Perioperative management of bilateral pheochromocytoma requires thorough preparation to reduce the consequences of hypotension, hypertension, hypoglycemia, hyperkalemia, and hyponatremia. Mortality of up to 50 % has been reported in the surgical resection of this tumor[2-5]. The challenges of the intraoperative team and how an anxious patient turned cooperative and pleasant shall be discussed.

Keywords: Bilateral Pheochromocytoma, Pediatric Pheochromocytoma.

INTRODUCTION

Pheochromocytoma is a rare but lethal disease in children and accounts for only about 0.1% percent of hypertensive pediatrics. The Philippine Pediatric Society's Pediatric Disease Registry program reported only 7 confirmed cases in the past twenty years according to the ICD code corresponding to Adrenomedullary Hyperfunction, which covers catecholamine secreting Pheochromocytomas.

There are currently no guidelines available to support a particular anesthetic drug or technique.

Randomized clinical trials would not be practical due to its scarcity. More extensive retrospective studies with a sufficient population may be useful in determining the outcomes of different management strategies to make more definitive recommendations. Sustained hypertension, attributed to secretion of norepinephrine, epinephrine, and dopamine were found in more than 60 % of cases. Other symptoms like headaches, excessive sweating, heart palpitations, chest pain, abdominal pain, nausea, vomiting, diarrhea, constipation, pallor, weakness, weight loss seizure, [6] and anxiety may also occur. If left untreated pheochromocytomas may cause serious, life- threatening complications, including cardiomyopathy, myocarditis, cerebral hemorrhage, and pulmonary edema. The only definitive treatment is surgical resection.

However, tumor resection should not be attempted without a comprehensive reoperative medical preparation to maintain volume status and counter all the catecholamine-induced cardiovascular effects that may occur intraoperatively. Thus, anesthetic management of pheochromocytoma is complicated and challenging, especially when both adrenals will be removed. A multidisciplinary team's intensive preoperative preparation, vigilant intraoperative, and comprehensive postoperative care are undeniably essential to provide the safest and optimal care to these patients.

CASE DESCRIPTION:

Our patient is a 12-year-old boy from Bataan, a son of an office worker mother. He weighed 36.5 kilograms with a height of 157cm. Nine months before admission, he had increasing episodes of headaches with no known triggers. He was given Paracetamol 500mg/tab one tablet as needed by his mother. Eight months before admission, the patient suddenly experienced successive seizure episodes described as body rigidity with upward rolling of the eyeballs accompanied by loss of consciousness. He consulted a nearby hospital in Bataan, where they first discovered he has hypertension (BP 220/110mmHg). A Whole abdomen CT scan

*3rd Place, 2020 Philippine Society of Anesthesiologists Inc. Interesting Case Presentation

[1]From University of Sto. Tomas Hospital

revealed two suprarenal masses on both sides, and his urine metanephrine test was elevated. Patient's mother revealed, she lost her husband due to pheochromocytoma five years ago (age = 35). After all work-ups were completed; he was diagnosed to have pheochromocytoma and was advised to go to Manila for further management.

He was given Metoprolol 50mg/tab one tab BID and Valproic Acid 500mg/tab one tab in AM and ½ tab in the evening, as take-home medications.

He sought consult and was admitted in our institution. He was admitted 1 month prior to the procedure for preoperative blood pressure control, oral Terazosin, 1mg/tab one tab every 12 hours was added to his other medications. The physical exam findings on admission revealed a well-nourished, conscious, coherent, not in cardiorespiratory distress boy. His vital signs were as follows: BP 154/82 mmHg, PR 103 bpm, RR 16-22/ CPM. His neurologic exam was normal. Likewise, all laboratories, including CBC, platelet, and chest x-ray, were normal.

Preoperatively, the patient fasted for more than 6 hours. However, venoclysis began soon as he was placed on NPO with D5NM at 76-77 cc/hr. A proton pump inhibitor was given at midnight. His maintenance medications were given at 5 am with 15 cc water. CBG monitoring done every 4 hours confirmed normoglycemia.

In the Operating Room, the patient had an NIBP, five lead ECG, and pulse oximeter. His initial vitals were: BP 176/94 mmHg, PR 124 bpm, RR of 18-20 CPM, and O2 saturation of 99% on room air. A Lumbar Epidural catheter was inserted on the first attempt, with the patient on his right lateral decubitus, with a Tuohy Gauge 20 needle. Insertion of the arterial line and IJ catheter were done after induction of general inhalational endotracheal anesthesia. Fentanyl and Nicardipine infusions were prepared and placed on standby before endotracheal intubation along with Epinephrine and Norepinephrine drips.

His vital signs before induction were as follows: BP 131/75 mmHg, PR 98 bpm, RR 20 CPM. Temperature: 36.7 C. He was induced with propofol 2.7mg/kg/IV, was administered Rocuronium 0.5 mg/kg, to facilitate endotracheal tube insertion, and maintained with sevoflurane at 3 volume %. His vitals immediately after intubation were:: BP 92/65 to 110/72 mmHg, Heart rate:72 -90 bpm. An endotracheal tube size 7.0 was secured after one attempt using direct laryngoscopy with Macintosh Blade 3.0 at level 19. An arterial line was placed on the left, while the IJ catheter was on the right internal jugular vein. A rectal probe was also inserted for temperature monitoring. At the initial stages of surgery, no elevations in BP and HR were noted.

However, soon as the right adrenal gland was manipulated, the patient's BP rose to 180-200 mmHg SBP. Thus, fentanyl infusion 2-3 mcg/kg/hr and nicardipine (0.5-3 mcg/kg/min) infusions were started. The patient's blood pressure dropped from 130 to 70 to 90 systolic when the right adrenal gland was detached. Therefore, the nicardipine drip was stopped, and the fentanyl drip was titrated. Norepinephrine and epinephrine drip was initiated at 0.02 to 0.20 mcg/kg/hour and titrated. Isolation of the left adrenal gland caused the same elevations of blood pressure, while its removal caused hypotension. The surgeon also disclosed he had inadvertently injured a part of the patient's inferior vena cava, which caused bleeding. Thus, immediately, one unit of prbc was transfused. The rest of the operation was uneventful. The team decided not to extubate the patient immediately, and titrated norepinephrine to maintain SBP to at least 100mmHg. CBG throughout the OR was noted to be within normal limits ranging from 80-112mg/ml.

He was transferred to the Pediatric Intensive Care Unit (PICU), still intubated for closer postoperative care. ABG done read compensated metabolic acidosis with adequate oxygenation. Sodium Bicarbonate was administered. Postoperative pain relief was through a continuous Bupivacaine 0.1% drip via the EC running at 20cc/hr combined with Paracetamol 8mg/kg/IV Q6 and Ketorolac 0.55mg/kg/IV Q6 and Hydrocortisone 10mg/IV. At the third hour of PICU stay, the patient spontaneously opened his eyes while breathing on his own. He was awake, alert, and follows directions. The patient also claimed to have a very mild pain score at 2/10. His vital signs were as

follows: BP 117-72, PR 88, RR 19, Spo2 99% on 5LPM face mask. Hydrocortisone was shifted from 10mg/IV to 6mg/tab every 12 hours. On subsequent visits to the patient, the patient was very cooperative and accommodating towards the team, no longer complains of headaches, and was cheerful and thankful.

DISCUSSION

Patients with pheochromocytoma have excessive stores of catecholamines in the sympathetic nerve terminals, and norepinephrine released from these terminals gets access to receptors on the effector cells readily.[6], Adrenoceptor overstimulation of catecholamines leads to the [7] signs and symptoms of pheochromocytoma. These catecholamine attacks can strike any time, resulting in serious hard to manage emergencies. Therefore, early diagnosis and surgical management are undeniably recommended. Though it is true, surgical removal of PCC is curative in 90% of the cases. However, in order to prevent catecholamine crisis, a comprehensive preoperative evaluation and preoperative preparation by the well- coordinated multidisciplinary team was key to the successful perioperative management of this case[8].

Blood pressure control for a minimum of 3-5 days
Systolic blood pressure value <130 mmHg*
Diastolic blood pressure values <80 mmHg*
Heart rate <80 beats/min
Orthostatic hypotension with blood pressure >80/45 mmHg
Ventricular arrhythmias <1 in 5 min
No ST-T wave changes in ECG
Hematocrit <45

The values may differ according to various institutional protocols and author preferences. *BP of <160/90 mmHg may be acceptable according to few authors. BP:Blood pressure, ECG:Electrocardiography

Table 1: Goals of preoperative alpha blockade [9]

Roizen *et al.* in 1982 proposed a set of criteria (now called the Roizen criteria) to objectively determine the adequacy of preoperative alpha blockade, and they include[10]:

1. No in-hospital blood pressure >160/90 mmHg for 24 h prior to surgery;
2. No orthostatic hypotension with blood pressure <80/45 mmHg;
3. No ST or T wave changes for 1-week prior to surgery;
4. No more than 5 premature Ventricular contractions per minute.

Mortality rates of pheochromocytoma resection was reported to decrease from 45% to 0% if patients were treated with alpha blockade.[10] Therefore, addition of Terazocin to the patient's maintenance meds was very valuable. Terazocin provided the necessary alpha blockade necessary to minimized the potential impact of an unopposed alpha vasoconstriction. Preoperative alpha blockade is crucial to maintain intraoperative hemodynamic stability and minimize morbidity during resection.[10] Phenoxybenzamine, a non-selective alpha adrenergic blocker, is the first line drug used for preoperative blockade, but is unavailable in the Philippines. Recently, Bongon et. al reported that Terazosin, a selective alpha-1 antagonist, at a maximum dose of 4 mg per day, may be safely given to Filipino patients diagnosed with pheochromocytoma for preoperative blockade. He further recommended its use as first line agent in the pre-operative management of pheochromocytoma in the Philippines[11]. From a hemodynamic perspective, few other clinical situations present a more complex and life-threatening situation than Pheochromocytoma resection. In this fragile perioperative environment, the anesthesiologist must be organized, systematic, prepared and well equipped in anticipation of the resections of the adrenal masses.

Relief from anxiety before anesthetic induction is essential, as fretfulness can predispose to catecholamine release. Administration of Midazolam .08mg/kg/IV and Fentanyl 0.5mcg/kg/IV was therefore given before induction to curtail hypertension. All vasopressor pumps were prepared and ready to be administered at any time. The epidural catheter was inserted with ease, and induction was stress-free. Induction was done with propofol because it has been documented as safe in these patients[12] Rocorunium was the muscle relaxant of choice because of its inability to cause histamine release.

Sevoflurane was used to maintain general anesthesia and was found to be the agent of choice forcardiovascular stability in pheochromocytoma.[13]

An arterial line was connected for a more accurate real-time blood pressure and volume status monitoring. An IJ catheter was also inserted to serve as wide bore access for fluid therapy and a port to the central vascular compartment for expeditious infusions of vasodilators and vasoconstrictors. The excellent outcome of this case may have been because of an effective preoperative blockade and an adequately filled volume compartment, having been prepared by the multidisciplinary team of physicians. The only challenge was when the surgeon started handling the tumor, which reoccurred with the second tumor manipulation. However, this was quickly corrected after titrating the vasopressors along with the judicious use of balanced crystalloids. Tumor manipulation usually generates dramatic pressor responses, which is expected because of the increases in levels of norepinephrine and epinephrine during tumor handling.[14] When the surgeon started tumor resection, it was noticeable that the patient had episodes of severe bradycardia, accompanied by episodes of hypertension and tachyarrhythmias, treated immediately by the prepared vasopressors. Blood transfusion was straightaway delivered when bleeding was perceived. Titrating the depth of anesthesia, rapidly administering direct arterial vasodilators, and blood curtailed any catastrophic hemodynamic consequences. It cannot be overstated that the anticipation and preparedness along with the knowledge and understanding of the pathophysiology and pharmacology was able to prevent any complication.

CONCLUSION AND RECOMMENDATIONS:

The anesthetic management of a child with pheochromocytoma poses significant challenges. Knowledge and understanding of pathophysiology and pharmacology are crucial to provide the safest anesthetic care. The comprehensive preparation and well-coordinated teamwork by the multidisciplinary team of doctors provided a suitable perioperative environment that effected a positive outcome. A further look into other anesthetic modalities such as the utility of thoracic epidural anesthesia, total intravenous anesthesia with propofol and remifentanil may prove beneficial in preventing the consequences of catecholamine surges of pheochromocytoma.

REFERENCES

1. Armstrong R, Sridhar M, Greenhalgh KL, Howell L, Jones C, Landes C, et al. Phaeochromocytoma in children. Arch Dis Child. 2008;93:899-9044
2. Hack HA. The perioperative management of children with phaeochromocytoma. Paediatr Anaesth. 2000;10(5):463-476
3. Martucci VL, Pacak K. Pheochromocytoma and paraganglioma: diagnosis, genetics, management, and treatment. Curr Probl Cancer. 2014;38(1):7-41.
4. Chen H, Sippel RS, O'Dorisio MS, et al. The North American Neuroendocrine Tumor Society consensus guideline for the diagnosis and management of neuroendocrine tumors: pheochromocytoma, paraganglioma, and medullary thyroid cancer. Pancreas. 2010;39(6):775-783.
5. Sbardella, E., & Grossman, A. B. (2019). Pheochromocytoma: An Approach To Diagnosis. Best Practice & Research Clinical Endocrinology & Metabolism, 101346. doi:10.1016/j.beem.2019.101346
6. Bravo EL: Evolving concepts in the pathophysiology, diagnosis, and treatment of pheochromocytoma. En- docr Rev 15:356-368, 1994
7. Ross, J. H. (2000). PHEOCHROMOCYTOMA. Urologic Clinics of North America, 27(3), 393–402. doi:10.1016/s0094-0143(05)70088-4
8. Aref, H., Safdar, O., Anshasi, W., & Alsharif, S. (2014). Bilateral adrenal pheochromocytoma in a 10-year old male patient. Journal of Pediatric Surgery Case Reports, 2(8), 400–402. doi:10.1016/j.epsc.2014.08.005
9. Pacak K. Preoperative management of the pheochromocytoma patient. J Clin Endocrinol Metab. 2007;92:4069–79
10. Roizen MF, Horrigan RW, Koike M, Eger IE, 2nd, Mulroy MF, Frazer B, et al. A prospective randomized trial of four anesthetic techniques for resection of pheochromocytoma. Anesthesiology. 1982;57:A43.)

11. Fleisher L and Mythen M. "Anesthetic implications of concurrent diseases". In: Miller's Anesthesia, 8th edition, Miller RD, Cohen NH, Eriksson LI., et al. (Eds), Elsevier, Philadelphia (2015): 1170.

12. Bongon, J., Oliva, R., Almelor, L., & Lantion-Ang, F. L. (2015). Terazosin as First Line Preoperative Blockade in Filipino Patients Diagnosed with Pheochromocytoma. Journal of the ASEAN Federation of Endocrine Societies, 30(1), 35. Retrieved from https://www.asean-endocrinejournal.org/ index.php/JAFES/articl e/view/171

13. Strebel S, Scheidegger D. Propofol-fentanyl anesthesia for pheochromocytoma resection. Acta Anaesthesiol Scand. 1991;35:275–7

14. Kinney MA, Narr BJ, Warner MA. Perioperative management of pheochromocytoma. J Cardiothorac Vasc Anesth. 2002;16(3):359-369. doi:10.1053/jcan.2002.124150

15. Vater M, Achola K, Smith G. Catecholamine responses during anaesthesia for phaeochromocytoma. Br J Anaesth. 1983;55:357–60